ELSEVIER
SAUNDERS

Clin Chest Med 25 (2004) 479–519

CLINICS
IN CHEST
MEDICINE

Drug-induced and iatrogenic infiltrative lung disease

Philippe Camus, MD*, Philippe Bonniaud, MD, Annlyse Fanton, MD, Clio Camus, MD, Nicolas Baudaun, MD, Pascal Foucher, MD

Department of Pulmonary Disease and Intensive Care, Hôpital du Bocage, Faculté de Médecine at Université de Bourgogne, 2 Bd Marechal de Lattre de Tasigny, 21034 Dijon Cedex, France

An ever-increasing number of drugs (350+) can cause injury to the lung parenchyma, upper and lower airways, pulmonary circulation, pleura, mediastinum, lymph nodes, and neuromuscular system. Infiltrative lung disease (ILD) is the most common pattern of drug-induced (DI) injury. A few drugs produce ILD as a manifestation of DI systemic autoimmune or hypersensitivity condition. Novel therapeutics, such as biologic agents (eg, colony stimulating factors, interferons [IFNs]) and disease-modifying drugs (anti–tumor necrosis factor [TNF] agents, monoclonal antibodies), also can produce ILD. In addition to prescription drugs, ionizing radiation, over-the-counter medicines, illicit substances, herbs, and dietary compounds also can produce ILD [1]. Drugs that cause ILD, the resulting pattern of involvement and the corresponding literature are available [2].

DI infiltrative lung disease include the following:

Interstitial lung disease (eg, DI nonspecific interstitial pneumonia [NSIP] or eosinophilic pneumonia)
Alveolar changes, which classically occur in DI-pulmonary edema, -hemorrhage, -diffuse alveolar damage, amiodarone (Am) pneumonitis, and exogenous lipoid pneumonia
Vasculitis

These three diseases can be present in association, particularly in patients who have severe drug-induced reactions. Patients with any of these three patterns of histopathologic involvement may present with similar pulmonary infiltrates on imaging.

Virtually all histopathologic subtypes of interstitial lung disease can be observed as the result of treatments with drugs [3]. These include cellular or fibrotic NSIP; a usual interstitial pneumonia-like pattern; eosinophilic pneumonia; organizing, lymphocytic, and desquamative interstitial pneumonia; and pulmonary granulomas. Alveolar changes include a lipid storage disease pattern, an alveolar proteinosis-like reaction, diffuse alveolar damage (DAD), pulmonary edema, and diffuse alveolar hemorrhage (DAH), with or without demonstrable capillaritis. The patterns of respiratory bronchiolitis-interstitial lung disease, alveolar microlithiasis, Langerhans cell granulomatosis, amyloid deposits, and centrilobular fibrosis are not associated with drug exposure. Drugs can produce more than one pattern of histopathologic involvement (eg, the overlap of organizing and eosinophilic pneumonia); this may create confusion, unless a specimen of significant size is available for histopathologic review. Drugs (eg, Am) can produce several distinct patterns of involvement. A few drugs, such as Am, kayexalate and mineral oil (paraffin), can produce a characteristic histopathologic pattern that often enables instant recognition of the drug etiology [4].

The occurrence of DI ILD is difficult to predict. Early detection remains a vexing problem that usually remains out of reach of serial chest radiographs or iterative measurements of pulmonary function [5]. There is virtually no reliable clinical, imaging, bronchoalveolar lavage (BAL), or histopathologic feature that is specific of, or diagnostic for, DI ILD

Space constraints did not allow for the inclusion of a reference on each statement. Specific queries on this and other aspects are welcome on Pneumotox at http://www.pneumotox.com.

* Corresponding author.
E-mail address: philippe.camus@chu-dijon.fr (P. Camus).

0272-5231/04/$ – see front matter © 2004 Elsevier Inc. All rights reserved.
doi:10.1016/j.ccm.2004.05.006

[4]. Therefore, it is crucial to the establishment of the diagnosis of DI ILD that a definite temporal relationship exists between exposure to the agent and the onset of the lung disease. The clinical severity of DI ILD ranges from subclinical pulmonary involvement with alveolitis in the BAL and no appreciable changes on imaging, vague pulmonary infiltrates and the asymptomatic state to diffuse consolidation and the adult respiratory distress syndrome (ARDS) that requires admission to the intensive care unit (ICU) and ventilatory support.

The quality of the evidence for proving causality with drugs in the literature is wide-ranging—from circumstantial in early or isolated case reports to supportive in larger, placebo-controlled studies or if the drug produces a suggestive temporal or histopathologic pattern of involvement. DI ILD must be differentiated from left ventricular failure, coincidental ILD, or an opportunistic infection. The last is an ever-present threat and a strong competing diagnosis in patients who receive immunosuppressive drugs [6]. The strength of the causal association also should be evaluated against the background of the basic disease for which the drug was given, which also can involve the lung in a manner similar to drugs. Diagnostic tools differ according to the clinical status of the patient; this creates diverse possible clinical scenarios that are relevant to the clinician.

DI ILD subsides upon drug discontinuance in most patients; however, corticosteroid therapy often is given, complicating the evaluation of drug causality. Thus, clinical status permitting, the suspected drug should be withdrawn and the patient observed until improvement occurs. DI ILD may, however, be severe or progress despite drug therapy withdrawal in a few patients, which necessitates corticosteroid therapy. Acute ILD still may cause fatalities [7]. Drug-induced pulmonary fibrosis generally is little improved following drug therapy withdrawal and corticosteroid therapy.

This article is clinically-oriented, rather than drug-oriented. The patterns of ILD that are produced by therapy drugs and radiation therapy are reviewed. The particulars of each drug are considered in Table 1 and are reviewed elsewhere [2,8].

Drugs that cause infiltrative lung disease

Drugs that often cause ILD include Am, antibiotics, nonsteroidal anti-inflammatory drugs (NSAIDs), chemotherapeutic agents (bleomycin, busulfan, chlorambucil, cyclophosphamide, methotrexate, mitomycin, nitrosoureas), and nitro-bearing drugs (nitrofurantoin, nilutamide). Recently, all-transretinoic acid (ATRA), colony-stimulating factors (CSFs), interferons, docetaxel, gefitinib, gemcitabine, irinotecan, vinorelbine, cytokines, and proteins (eg, plasma fraction, intravenous immunoglobulins [IVIG], and antithymocyte globulin [ATG]) were shown to cause pulmonary injury [2].

DI ILDs have changed with time. Organizing pneumonia that was due to the earlier antihypertensive drugs and pulmonary granulomatosis that resulted from the inhalation of pituitary snuff have disappeared. DI ILD also has changed in patients who have rheumatoid arthritis, with an increase in the incidence of methotrexate pneumonitis and of tuberculosis after treatments with anti-TNF agents. These are in contrast with gold lung and the complications of penicillamine that were seen formerly and decreased in frequency because these drugs are used less often. Likewise, nitrofurantoin lung has decreased in frequency from a high in the 1960s to a low in the late 1980s. Cases of nitrofurantoin lung are on the increase again as the drug regains popularity among urologists. Am lung was first described in the 1980s and many novel chemotherapeutic agents (eg, gemcitabine, irinotecan, imatinib, gefitinib) are associated with the development of sometimes severe ILD [2]. Drugs that cause ILD, including those that have been recalled in the past are available at www.pneumotox.com [2].

The prevalence of DI ILD ranges from approximately 1 in 100,000 treatments for nitrofurantoin, to several percent in patients who take Am, to greater than 40% in women who receive nitrosourea-based chemotherapy for the treatment of high-risk breast cancer. Pneumotox provides a rough estimate of the prevalence rate for each drug [2]. The oral and parenteral route are cited more frequently as the origin of DI-ILD; however, drugs can produce ILD after inhaled, topical (ophthalmic, dermal, nasal), intrathecal, intracavitary, and intra-arterial administration. Sometimes, ILD results from an overdose of the drug (eg, anticoagulant-induced alveolar hemorrhage, aspirin-or tricyclic antidepressant–induced pulmonary edema) or is related to the pharmacologic action of the drug (eg, the dyslipidosis induced by Am). More commonly, however, DI-ILD occurs unexpectedly as a idiosyncratic reaction in a few patients which makes prevention difficult.

Certain drugs tend to cause a stereotypical pattern of ILD. For instance, minocycline produces eosinophilic pneumonia, whereas methotrexate causes an acute granulomatous ILD, which mimics an infection. Others, such as Am or bleomycin, can cause a collection of syndromes that range from pulmonary infiltrates and the asymptomatic state to dense symp-

tomatic NSIP, pulmonary infiltrates and eosinophilia (PIE), organizing pneumonia (OP), multiple round nodules, ARDS, and irreversible pulmonary fibrosis [2]; this makes recognition and diagnosis of the drug etiology more problematic.

Several drugs of a given therapeutic class may induce the same pattern of ILD, which suggests a common cytopathic mechanism. For instance, NSAIDs and certain antibiotic drugs tend to produce PIE, whereas alkylating agents produce alveolar damage with pneumocyte dysplasia or pulmonary fibrosis. Similar observations exist for other drug-related injuries. For instance, ergot drugs collectively produce pleural or pericardial thickening and NSAIDs produce acute bronchospasm. In contrast, many chemically-unrelated drugs can produce cellular NSIP; this suggests that either that the lung response to these drugs is nonspecific or that it is unrelated to the pharmacologic action of the particular drug.

In contrast to allergic and anaphylactic reactions, true cross-reactivity has been documented rarely with drugs that cause ILD. Accordingly, resuming treatment with a chemically-related drug is generally considered to be safe. Anticonvulsants and chemotherapeutic agents are exceptions, because further treatment with a drug congener may aggravate or exacerbate the ILD.

Diagnostic criteria

A high index of suspicion is needed. The criteria for the diagnosis of DI ILD are discussed in the following sections.

Correct identification of the drug

A meticulous history taking of current or recent exposure to prescription drugs, radiation, over-the-counter medications, dietary compounds, herbs, home-made products, and odd substances is warranted. Remote exposure to radiation and drugs (up to several years before) may cause ILD later in life [9].

Singularity of the drug

Patients can be exposed concurrently to several pneumotoxic drugs. This may create confusion about which drug is more likely to be responsible for the lung disease. The respective likelihood is evaluated against the incidence rate of pulmonary adverse effects and pattern of lung response for each drug.

Temporal eligibility

The onset of symptoms must be associated temporally with drug administration and evidence for ILD should be absent before treatment with the suspected drug. Thus, review of all available chest films is required. The time to onset of the ILD is variable. It may take as little as a few seconds, minutes, or hours for pulmonary edema or alveolar hemorrhage to develop after administration of radiographic contrast media or anticoagulants, respectively. The latency period for most other drugs that cause ILD is weeks to years. The shorter the latency period, the easier it is to recognize the drug cause. Why DI lung disease develops unexpectedly after years of treatment remains unclear; coincidental infection or other danger signals are a possibility [10].

Ideally, all signs and symptoms that are related to the ILD should clear after discontinuance of the specific drug. The effects of drug dechallenge are less in patients who have DI pulmonary fibrosis. If possible, corticosteroid therapy should not be given so that the effect of drug dechallenge can be evaluated. Corticosteroid therapy is recommended, however, in patients who have severe DI-ILD because they may not improve after removal of the drug.

Recurrence with rechallenge is central to the diagnosis of DI ILD. This seldom is performed intentionally, however, because pulmonary reactions of increased severity and death may ensue which raises evident ethical issues [7]. Only patients who demonstrated mild ILD may be rechallenged—after informed consent—and if no alternate therapy drug is available.

Characteristic clinical, imaging, bronchoalveolar lavage, and pathologic pattern of the reaction to the specific drug

Generally, the clinical, imaging, and BAL features are consistent with, rather than suggestive or diagnostic of, the drug etiology. The high-resolution CT (HRCT) scan is more sensitive than is the plain chest radiograph to detect early changes on imaging and also can be used to choose the area of lung to sample or biopsy; however, the HRCT also is nonspecific [11]. A pathognomonic histopathologic pattern of reaction to the particular drug rarely is present [4], except for Am pneumonitis and exogenous lipoid pneumonia. More often, the lung biopsy excludes the presence of pulmonary involvement from the underlying disease or an infection and determines whether the pulmonary reaction is consistent with a

Table 1
Drugs that cause infiltrative lung disease and the resulting clinical radiographic and pathologic patterns

	Acute ILD	Subacute ILD	PIE	Granulomatous ILD	Organizing pneumonia	DIP	Pulmonary fibrosis	Shrinking lung	Subclinical involvement	Diffuse calcifications	Lipid pneumonia	Lung nodules
Abacavir												
Abciximab												
Acebutolol		2			2							
Acetaminophen			1									
Acetylsalicylic acid (aspirin)			1									
Acitretin	1											
Acyclovir		1										
Adrenalin (epinephrine)												
Albumin												
Allopurinol												
Aminoglutethimide			(1)									
Amiodarone		4	1		3		3					2
Amitriptyline			1									
Amphotericin B					1							
Ampicillin		1	1									
Amrinone		1										
Anagrelide	1											
Angiotensin convertase inhibitors		1	2									
Antazoline		1										
Antithymocyte globulin							1					
Atenolol		1										
Aurothiopropanosulfate (gold salt)	2	2	2	2	1		2					
Azapropazone		1										
Azathioprine		2										
Azithromycin			1									
Barbiturates					1							
BCG therapy (intravesical)	3	2		2/3								
Beclomethasone			1									
Bepridil							1					
Betaxolol					1							
Bicalutamide		1	1									
Bleomycin		3	2		3		3					3
Blood transfusions												
Bromocriptine							2					

(continued on next page)

Table 1 (*continued*)

	Transient infiltrates	Pulmonary edema	ARDS	HUS	DAH	SLE	PVOD	Pulmonary or systematic vasculitis	Fat metabolism	DIHSS	Opportunistic infections
Abacavir										1	
Abciximab					1						
Acebutolol						3					
Acetaminophen											
Acetylsalicylic acid (aspirin)		3	1		1			1		1	
Acitretin											
Acyclovir											
Adrenalin (epinephrine)		2									
Albumin		1									
Allopurinol								1			
Aminoglutethimide											
Amiodarone			2		1	2					
Amitriptyline		1	1								
Amphotericin B		2	2								
Ampicillin											
Amrinone											
Anagrelide											
Angiotensin convertase inhibitors						2					
Antazoline											
Antithymocyte globulin	1	2									
Atenolol							1				
Aurothiopropanosulfate (gold salt)											
Azapropazone											
Azathioprine					1						
Azithromycin								1			
Barbiturates											
BCG therapy (intravesical)			1								3
Beclomethasone											2
Bepridil											
Betaxolol											
Bicalutamide											
Bleomycin			3				1				
Blood transfusions		3	2								
Bromocriptine											

(continued on next page)

Table 1 (*continued*)

	Acute ILD	Subacute ILD	PIE	Granulomatous ILD	Organizing pneumonia	DIP	Pulmonary fibrosis	Shrinking lung	Subclinical involvement	Diffuse calcifications	Lipid pneumonia	Lung nodules
Bucillamine			1									
Buprenorphine												
Busulfan		1				1	3					
Calcium salts										1		
Camptothecin			1									
Captopril		1	1									
Carbamazepine	2	2	2		1							1
Carbimazole												
Carmustine (BCNU)		2					3					
Cefotiam			1									
Celiprolol	1											
Cephalexin			1									
Cephalosporins			1		1							
Chlorambucil		1					2					
Chlorhexidine												
Chloroquine			1									
Chlorozotocin (DCNU)							1					
Chlorpromazine			1									
Chlorpropamide			1									
Cladribine			1									
Clindamycin			1									
Clofazimine									1			
Clofibrate			1									
Clomiphene												
Clonidine												
Clopidogrel												
Clozapine		1	1									
Colchicine												
Contraceptives (oral)												
Cotrimoxazole	1	1	1									
Cromoglycate			1									
Cyclophosphamide		2			1		2					
Cyclosporine		1									1	
Cyproterone acetate		1	1									
Cytosine arabinoside (ara-c)												

(continued on next page)

Table 1 (*continued*)

	Transient infiltrates	Pulmonary edema	ARDS	HUS	DAH	SLE	PVOD	Pulmonary or systematic vasculitis	Fat metabolism	DIHSS	Opportunistic infections
Bucillamine											
Buprenorphine		2									
Busulfan							1				
Calcium salts											
Camptothecin		1	2								
Captopril											
Carbamazepine		1			1	1				2	
Carbimazole								1			
Carmustine (BCNU)			3				1				
Cefotiam											
Celiprolol											
Cephalexin											
Cephalosporins											
Chlorambucil			1								
Chlorhexidine			1								
Chloroquine											
Chlorozotocin (DCNU)											
Chlorpromazine		1				1					
Chlorpropamide										1	
Cladribine											
Clindamycin											
Clofazimine											
Clofibrate						1					
Clomiphene		2	1								
Clonidine						1					
Clopidogrel					1						
Clozapine											
Colchicine		1								1	
Contraceptives (oral)						1	1				
Cotrimoxazole		1								1	
Cromoglycate											
Cyclophosphamide		1	2								2
Cyclosporine		1			1						2
Cyproterone acetate											

(continued on next page)

Table 1 (*continued*)

	Acute ILD	Subacute ILD	PIE	Granulomatous ILD	Organizing pneumonia	DIP	Pulmonary fibrosis	Shrinking lung	Subclinical involvement	Diffuse calcifications	Lipid pneumonia	Lung nodules
Danazol							1					
Dapsone			1									
Deferoxamine												
Desipramine			1									
Dextran 70												
Diclofenac			1									
Diflunisal			1									
Dihydroergocryptine		1			1							
Dihydroergotamine					1							
Diltiazem												
Dimethylsulfoxide (DMSO)												
Docetaxel	1	1										
Dothiepin		1					1					
Efavirenz												
Epoprostenol (see prostacyclin)												
Ergometrine												
Ergotamine		1					1					
Erythromycin			1									
Etanercept												
Ethambutol			1									
Ethchlovrynol												
Etoposide		1										
Etretinate												
Febarbamate			1									
Fenbufen			1									
Fenfluramine/dexfenfluramine		1	1									
Fenoprofen			1									
Fibrinolytics (including RTPA)												
FK506					1							
Flecainide		2										
Floxuridine		1										
Fludarabine	1	1										
Fluoresceine												
5-fluorouracil							1					
Fluoxetine		1										

(continued on next page)

Table 1 (*continued*)

	Transient infiltrates	Pulmonary edema	ARDS	HUS	DAH	SLE	PVOD	Pulmonary or systematic vasculitis	Fat metabolism	DIHSS	Opportunistic infections
Cytosine arabinoside (ara-c)		2	2		1						
Danazol											
Dapsone										1	
Deferoxamine		1	1								
Desipramine											
Dextran 70		1			1						
Diclofenac											
Diflunisal								1			
Dihydroergocryptine											
Dihydroergotamine											
Diltiazem		1									
Dimethylsulfoxide (DMSO)					1						
Docetaxel	1	1	1		1						
Dothiepin											
Efavirenz										1	
Epoprostenol (see prostacyclin)		1									
Ergometrine		1									
Ergotamine											
Erythromycin		1	1					1			
Etanercept						1					1
Etanercept											
Ethambutol											
Ethchlovrynol		2									
Etoposide		1									
Etretinate			1								
Febarbamate											
Fenbufen											
Fenfluramine/dexfenfluramine											
Fenoprofen											
Fibrinolytics (including RTPA)					2						
FK506											
Flecainide											
Floxuridine											
Fludarabine			1		1						

(continued on next page)

Table 1 (*continued*)

	Acute ILD	Subacute ILD	PIE	Granulomatous ILD	Organizing pneumonia	DIP	Pulmonary fibrosis	Shrinking lung	Subclinical involvement	Diffuse calcifications	Lipid pneumonia	Lung nodules
Flutamide		1										
Fluvastatin												
Fosinopril			1									
Fotemustine							1					
Furazolidone			1									
G/GM-CSF		1	1									
Gemcitabine		1										
Glafenine			1									
Glibenclamide		1										
Haloperidol												
Heparins												
Heroin		1										
Hexamethonium (discontinued)					(3)							
Hydralazine/dihydralazine		1			1							
Hydrochlorothiazide		1	1									
Hydroxyquinoline		1										
Hydroxyurea		1										
Ibuprofen			1									
Ifosfamide		1					1					
Imipramine			1									
Immunoglobulins (IVIG)												
Indinavir												
Indomethacin			1									
Infliximab												
Insulin												
Interferon-α		1		1	1	1						
Interferon-β		1			1							
Interleukin-2			1									
Irinotecan		1										
Isoniazid			1									
Isotretinoin			1									
Ketamine												
Labetalol			1				1					
I-asparaginase												
I-dopa												

(continued on next page)

Table 1 (*continued*)

	Transient infiltrates	Pulmonary edema	ARDS	HUS	DAH	SLE	PVOD	Pulmonary or systematic vasculitis	Fat metabolism	DIHSS	Opportunistic infections
Fluoresceine		1									
5-fluorouracil			1								
Fluoxetine										1	
Flutamide											
Fluvastatin			1			1					
Fosinopril											
Fotemustine			2								
Furazolidone											
G/GM-CSF	2		2								
Gemcitabine			2								
Glafenine											
Glibenclamide										1	
Haloperidol			1								
Heparins			2		1						
Heroin		3									
Hexamethonium (discontinued)											
Hydralazine/dihydralazine					1	2					
Hydrochlorothiazide		3	2								
Hydroxyquinoline											
Hydroxyurea											
Ibuprofen		1									
Ifosfamide		1	1								
Imipramine											
Immunoglobulins (IVIG)		1	1								
Indinavir			1								
Indomethacin											
Infliximab											2
Insulin		1									
Interferon-α											
Interferon-β											
Interleukin-2		3	2								
Irinotecan		2	2								
Isoniazid						2					
Isotretinoin											

(continued on next page)

Table 1 (*continued*)

	Acute ILD	Subacute ILD	PIE	Granulomatous ILD	Organizing pneumonia	DIP	Pulmonary fibrosis	Shrinking lung	Subclinical involvement	Diffuse calcifications	Lipid pneumonia	Lung nodules
Leukotriene antagonists			1									
Leuprorelin		1										
Levofloxacin			1									
Lidocaine												
Intravenous lipids												
Lomusstine CCNU		1					2					
Loxoprofen			1									
Maprotiline		1	1									
Mecamylamine					(2)							
Mefloquine		1										
Melphalan		1					2					
Mephenesin			1									
6-Mercaptopurine		1										
Mesalamine/mesalazine			2		2							
Metapramine		1										
Metformine		1										
Methadone												
Methotrexate	4	3	1	4			1					
Methyldopa												
Methylphenidate			1									
Methysergide							1[a]					
Metronidazole			1									
Miconazole												
Minocycline			3		1			1				1
Mitomycin C		1					2					
Mitoxantrone		1										
Montelukast			1									
Moxalactam												
Mycophenolate mofetil							1					
Nadolol		1										
Nafazoline												
Nalbuphine												
Nalfon			1									
Nalidixic acid		1	1									
Naloxone												

(continued on next page)

Table 1 (*continued*)

	Transient infiltrates	Pulmonary edema	ARDS	HUS	DAH	SLE	PVOD	Pulmonary or systematic vasculitis	Fat metabolism	DIHSS	Opportunistic infections
Ketamine											
Labetalol						2					
I-asparaginase		2									
I-dopa						1					
Leukotriene antagonists								2			
Leuprorelin			1								
Levofloxacin											
Lidocaine		1									
Intravenous lipids			1						1		
Lomusstine CCNU			2				1				
Loxoprofen											
Maprotiline											
Mecamylamine											
Mefloquine			1								
Melphalan											
Mephenesin											
6-Mercaptopurine											
Mesalamine/mesalazine											
Metapramine											
Metformine											
Methadone		1									
Methotrexate		2	2		1						3
Methyldopa						2					
Methylphenidate								1			
Methysergide											
Metronidazole											
Miconazole			1								
Minocycline		1				2		1		2	
Mitomycin C		2	2	3	2						
Mitoxantrone											
Montelukast								2			
Moxalactam					1						
Mycophenolate mofetil			1								
Nadolol											

(continued on next page)

Table 1 (*continued*)

	Acute ILD	Subacute ILD	PIE	Granulomatous ILD	Organizing pneumonia	DIP	Pulmonary fibrosis	Shrinking lung	Subclinical involvement	Diffuse calcifications	Lipid pneumonia	Lung nodules
Naproxen			2									
Nevirapine												
Niflumic acid			1									
Nilutamide	1	3	1		1							
Niridazole			1									
Nitric oxide												
Nitrofurantoin	4	3	1		1	1	2	1	1			
Nitroglycerin												
Nitrosoureas		2					3					
Nomifensine		1	1									
NSAID			3									
Noramidopyrine (metamizole)												
Oestrogens												
OKT3												
Olsalazine												
Oploids (morphine agonist / antagonist)												
Oral anticoagulants												
Ornipressin												
Oxprenolol		1										
Oxphenbutazone		1										
Paclitaxel		1	1									
Para(4)-aminosalicylic acid (pas)			2									
Paraffin (mineral oil)											4	
Parenteral nutrition												
Penicillamine		2	1		1		1					
Penicillins			2									
Pentamidine			1									
Perindropril			1									
Phenylbutazone			1									
Phenylephrine												
Phenytoin		2	2		1							1
Pindolol							1					
Piroxicam			1									
Pituitary snuff		1		1								
Plasma (fresh frozen)												

(continued on next page)

Table 1 (*continued*)

	Transient infiltrates	Pulmonary edema	ARDS	HUS	DAH	SLE	PVOD	Pulmonary or systematic vasculitis	Fat metabolism	DIHSS	Opportunistic infections
Nafazoline		1									
Nalbuphine		1									
Nalfon											
Nalidixic acid						1					
Naloxone		1									
Naproxen											
Nevirapine										1	
Niflumic acid											
Nilutamide											
Niridazole											
Nitric oxide		1									
Nitrofurantoin	2	1	1		1	1		2		1	
Nitroglycerin		1									
Nitrosoureas			2				1				
Nomifensine								1			
NSAID		1								2	
Noramidopyrine (metamizole)		1									
Oestrogens							1				
OKT3			1								
Olsalazine						1					
Oploids (morphine agonist / antagonist)		3									
Oral anticoagulants					2						
Ornipressin		1									
Oxprenolol											
Oxphenbutazone											
Paclitaxel	1										
Para(4)-aminosalicylic acid (pas)		1									
Paraffin (mineral oil)											
Parenteral nutrition									2		
Penicillamine			1		2						
Penicillins								1			
Pentamidine											
Perindropril											

(continued on next page)

Table 1 (*continued*)

	Acute ILD	Subacute ILD	PIE	Granulomatous ILD	Organizing pneumonia	DIP	Pulmonary fibrosis	Shrinking lung	Subclinical involvement	Diffuse calcifications	Lipid pneumonia	Lung nodules
Practolol (recalled)		(1)					(1)					
Pranlukast	1											
Pranoprofen			1									
Pravastatin					1							
Procainamide		1										
Procarbazine	1	1	1				1					
Propofol												
Propoxyphene												
Propranolol			1									
Propylthiouracil		1	1									1
Prostacyclin												
Protamine												
Pyrimethamine-dapsone			1									
Pyrimethamine-sulfadoxine		1	1									
Quinidine		1										
Radiation therapy	2	2			2		4	2	2			
Radiographic contrast media			1									
Raltitrexed		1										
Retinoic acid (ATRA)												
Rifampin			1									
Ritodrine												
Rituximab						1						
Roxithromycin			1									
Salbutamol (infected)												
Serrapeptase			1									
Sertraline			1									
Simvastin		1	1		1							
Sirolimus (rapamycin)		1										
Sotalol					1							
β2-agonists (administered IV in OB/GYN												
Steroids												
Streptokinase												
Streptomycin			1									
Sulfamides-sulfonamides		1	2									
Sulfasalazine		1	2			1	1					

(continued on next page)

Table 1 (*continued*)

	Transient infiltrates	Pulmonary edema	ARDS	HUS	DAH	SLE	PVOD	Pulmonary or systematic vasculitis	Fat metabolism	DIHSS	Opportunistic infections
Phenylbutazone		1								1	
Phenylephrine		1									
Phenytoin					1	1		1		1	
Pindolol						1					
Piroxicam											
Pituitary snuff											
Plasma (fresh frozen)		2									
Practolol (recalled)											
Pranlukast								1			
Pranoprofen											
Pravastatin											
Procainamide						2					
Procarbazine											
Propofol	1								1		
Propoxyphene		1									
Propranolol		1				2					
Propylthiouracil			1		1			2			
Prostacyclin		2									
Protamine		1	1								
Pyrimethamine-dapsone										1	
Pyrimethamine-sulfadoxine		1									
Quinidine					1	1					
Radiation therapy			2				2				1
Radiographic contrast media		2	2		1						
Raltitrexed											
Retinoic acid (ATRA)	1	2	2		2						
Rifampin											
Ritodrine		3									
Rituximab											
Roxithromycin								1			
Salbutamol (infected)		3									
Serrapeptase											
Sertraline											
Simvastin			1			1					

(continued on next page)

Table 1 (*continued*)

	Acute ILD	Subacute ILD	PIE	Granulomatous ILD	Organizing pneumonia	DIP	Pulmonary fibrosis	Shrinking lung	Subclinical involvement	Diffuse calcifications	Lipid pneumonia	Lung nodules
Sulindac			1	1								
Tacrolimus					1							
Tamoxifen							1					
Tenidap			1									
Terbutaline												
Tetracycline			2									
Thalidomide		1										
Tiaprofenic acid			1									
Ticlopidine			1		1							
Tiopronin		1										
Tirofiban												
TNF-α												
Tocainide		1					1					
Tolazamide			1									
Tolfenamic acid			1									
Topotecan					1							
Tosufloxacin			1									
Trazodone			1									
Triazolam												
Tricyclic antidepressants												
Trimipramine			1									
Troglitazone												
Troleandomycin			1									
I-tryptophan			(4)		(1)							
Urokinase												
Valproate (valproic acid)												
Valsartan		1										
Vasopressin												
Venlafaxine			1									
Vinblastine												1
Vindesine	1											
Vinorelbine												
Vitamin D										1		
Zafirlukast			1									

(continued on next page)

Table 1 (*continued*)

	Transient infiltrates	Pulmonary edema	ARDS	HUS	DAH	SLE	PVOD	Pulmonary or systematic vasculitis	Fat metabolism	DIHSS	Opportunistic infections
Sirolimus (rapamycin)					1						
Sotalol											
β2-agonists (administered IV in OB/GYN		3									
Steroids											3
Streptokinase			1		2						
Streptomycin											
Sulfamides-sulfonamides		1	1			1		2			
Sulfasalazine		1				1		1			
Sulindac										1	
Tacrolimus											
Tamoxifen		1									
Tenidap											
Terbutaline		3									
Tetracycline						2					
Thalidomide											
Tiaprofenic acid											
Ticlopidine											
Tiopronin											
Tirofiban					1						
TNF-α		2			1						
Tocainide											
Tolazamide											
Tolfenamic acid											
Topotecan	2		2								
Tosufloxacin											
Trazodone											
Triazolam		1									

(continued on next page)

Table 1 (*continued*)

	Transient infiltrates	Pulmonary edema	ARDS	HUS	DAH	SLE	PVOD	Pulmonary or systematic vasculitis	Fat metabolism	DIHSS	Opportunistic infections
Tricyclic antidepressants		2									
Trimipramine											
Troglitazone		1									
Troleandomycin											
I-tryptophan								(4)			
Urokinase					2						
Valproate (valproic acid)					1						
Valsartan											
Vasopressin		1									
Venlafaxine											
Vinblastine		1	1								
Vindesine			1	1							
Vinorelbine		1									
Vitamin D											
Zafirlukast								1			

Drugs that cause pulmonary edema or (ARDS) may cause transient pulmonary infiltrates in some patients.
Figures in boxes indicate the frequency of the adverse effect: from 1 (rare) to 4 (common).
Empty boxes: adverse effect not reported.
Parentheses indicate that the drug was recalled (eg, hexamethonium, practolol).
When most drugs in a therapeutic induce similar adverse effects in the lung (eg, angiotensin-converting enzyme inhibitors, (β-blockers, β2 agonists, leukotriene antagonisis, nonsteroidal anti-inflammatory drugs [NSAIDs]) the family of drugs is mentioned, not all particular drugs in the class.
Abbreviations: BCG, bacille Calnette-Guérin; DIHSS, drug-induced hypersensitivity syndrome; DIP, desquamative interstitial pneumonia; FK506, tacrolimus; G/GM-CSF, granulocyte or granulocyte-macrophage colony-stimulating factor; HUS, hemolytic uremic syndrome; PIE, pulmonary infiltrates and eosinophilia; PVOD, pulmonary veno-occlusive disease; SLE, systemic lupus erythematosus.

[a] The pulmonary fibrosis of methysergide and of other ergots is associated closely with pleural fibrosis, the predominant adverse effect from these drugs.

particular drug [4]. The histopathologic pattern of lung response (eg, the amount of 'fibrosis') also may help to evaluate the prognosis.

A few drugs or procedures, however, produce a distinctive pattern of ILD:

- Radiation therapy to the chest typically localizes to the irradiated area [12]
- Nitrofurantoin occasions an early and acute form of ILD with intense symptoms that contrast with minimal radiographic changes, or a subacute or chronic form that is characterized by peribronchovascular shadowing and the histopathologic pattern of desquamative interstitial or OP, or fibrosis.
- Methotrexate causes a distinctive granulomatous ILD that mimics an infection.
- Bleomycin can produce basilar subpleural infiltrates with severe volume loss or multiple lung nodules.
- Mitomycin C produces the hemolytic and uremic syndrome with hemolysis, renal failure, acute pulmonary hypertension, and ARDS.
- Am and mineral lipids cause endogenous or exogenous lipoid pneumonia, respectively, with distinctive imaging, BAL, and histopathologic features.

Exclusion of other causes for the interstitial lung disease

This often is a difficult exercise, because the background neoplastic or inflammatory/autoimmune disease or an infection also can produce ILD. Pulmonary congestion should be ruled out by diuresis, and body fluids and BAL should be sampled to measure autoantibodies and to look for an infection. A lung biopsy may be required in selected cases, but pathology may not solve the issue.

In vitro tests

Quantification of drug levels in blood or lung tissue may be necessary to confirm an adverse reaction that results from drug overdose (eg, aspirin, anticoagulants, tricyclics). Other in vitro tests (eg, monocyte migration, proliferation and transformation of blood or BAL lymphocytes and cytotoxicity assays in the presence of the drug or the drug and a metabolic activating system) have not yielded clinically useful results.

Clinical scenarios that are relevant to the pulmonologist

Acute life-threatening drug-induced infiltrative lung disease

Drugs can produce respiratory emergencies, including widespread pulmonary infiltrates, with compromise of gas exchange and life-threatening respiratory failure [13]. This may correspond to acute:

- Interstitial pneumonitis with (eg, with methotrexate, interferons, or bacille Calmette-Guérin [BCG]-therapy) or without (eg, with chrysotherapy, or β-blockers) granulomas (Fig. 1)
- Eosinophilic pneumonia (eg, with minocycline, NSAIDs, or angiotensin-converting enzyme inhibitors (ACEI) (Fig. 2)
- Diffuse alveolar damage (eg, with chemotherapeutic agents, or aspirin) (Fig. 3)
- Alveolar hemorrhage (eg, with anticoagulants or inhibitors of platelet functions). More than one of the aforementioned histopathologic features may be present in a lung biopsy specimen (see Fig. 3).
- Am pulmonary toxicity (Fig. 4)
- Pulmonary edema (eg, with aspirin, hydrochlorothiazide, blood transfusions (the transfusion-related acute lung injury [TRALI] syndrome [14]), or tricyclic antidepressants) (Fig. 5)
- Rarely, acute OP (eg, with interferon-α or -β, nitrofurantoin or statins) (Fig. 6)

Early recognition of the drug etiology, attempts to identify the background of ILD using the least invasive methods, exclusion of an infection, prompt drug withdrawal and judicious use of corticosteroids are essential steps in the management of acute ILD.

Patients who have acute DI-ILD present with the progressive or abrupt development of nonproductive cough, fever, dyspnea, and pulmonary infiltrates that culminate in acute hypoxemic respiratory failure or ARDS. In patients who have moderate DI-ILD, failure to recognize the drug etiology and to discontinue the causative drug in time can lead to acute DI-ILD (Fig. 8). Typically, patients require admission to the ICU and ventilatory support and are too ill to undergo detailed evaluation of lung volume or measurements of the diffusing capacity for carbon monoxide (KCO).

It is notoriously difficult to infer the pathologic background of pulmonary infiltrates from their appearances on the chest radiograph or HRCT [11]. Imaging also may not enable the distinction between

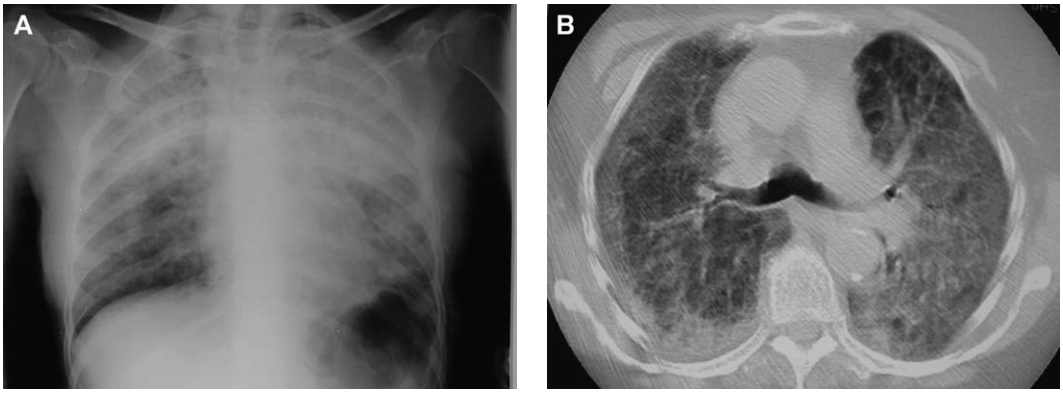

Fig. 1. Methotrexate lung often is in the form of acute cellular interstitial pneumonia that creates dense pulmonary infiltrates and confluences. The condition commonly has a fulminant course, often preceded by days or a few weeks with dry cough dyspnea and fever. (*A*) Radiograph. (*B*) On CT there is a diffuse haze or areas on consolidation with air bronchograms. Severe forms of methotrexate lung may be complicated by superimposed pulmonary edema or alveolar hemorrhage. Outcome was favorable in this patient after drug therapy withdrawal without the recourse to corticosteroid therapy.

ILD and an infection [15]. The diagnosis of DI hypersensitivity pneumonitis, acute eosinophilic pneumonia, and chemotherapy lung is aided when increased numbers of lymphocytes, eosinophils, or dysplastic type II cells are present in the BAL, respectively. No consistent BAL pattern has been reported in acute Am pulmonary toxicity. Macroscopically in alveolar hemorrhage, the BAL is hemorrhagic and demonstrates increased bleeding in sequential aliquots. The BAL also is helpful to exclude an infection, most notably with *Pneumocystis jiroveci*, in patients who are on immunosuppressive drugs [6]. An open lung biopsy may be required in selected cases to rule out involvement from the background disease or an infection, and to evidence one of the above histopathologic patterns, which may be consistent with the drug etiology. Overall, methotrexate, Am, and chemotherapeutic agents are the drugs that cause acute ILD most often.

Acute methotrexate lung

Acute methotrexate lung (see Fig. 1) is the most common pattern of DI ILD. The condition develops in 0.3% to 11.6% of patients, after variable time into treatment for inflammatory conditions, mainly rheu-

Fig. 2. Radiograph showing acute eosinophilic pneumonia that can produce diffuse infiltrates and acute respiratory failure. The condition is diagnosed by the finding of eosinophils in peripheral blood or BAL. Outcome was favorable in this case associated with minocycline exposure. (Courtesy of F. de Blay, MD, Strasbourg, France.)

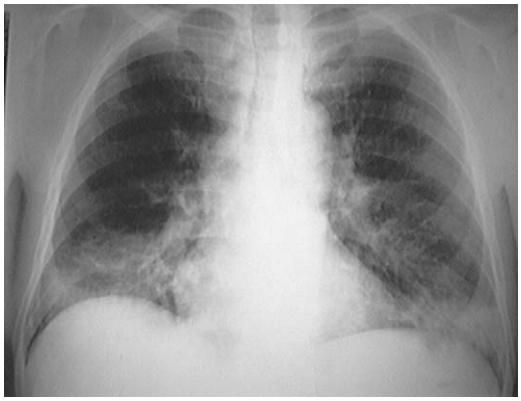

Fig. 3. Radiograph showing diffuse alveolar damage. The condition typically results from exposure to chemotherapeutic agents or radiation therapy (deteriorating busulfan lung here). This patient died from pneumonia after a lung biopsy procedure. (Courtesy of R. Putelat, MD, Dijon, France.)

Fig. 4. Radiograph showing acute amiodarone pulmonary toxicity (APT) that developed as a de novo phenomenon. Diuresis produced no change in alveolar infiltrates and there was no increase in vascularity. A working diagnosis of APT was thus entertained. Drug therapy withdrawal (with clearance from the cardiologist) and corticosteroid therapy were followed by slow improvement. (Courtesy of J.M. Petit, MD, Dijon, France.)

matoid arthritis or hematologic malignancies [16,17]. Whether acute methotrexate lung is a peculiar pattern of lung response to the drug or simply is the result of late diagnosis of a milder form of the disease is unknown. Risk factors include diabetes mellitus, hypoalbuminemia, pleuropulmonary involvement from rheumatoid arthritis, previous use of disease-modifying drugs, and older age [17]. Full-blown disease is preceded by a dry cough, dyspnea, and fever for a few days, whereas the chest radiograph may remain normal. On imaging, there is the pattern

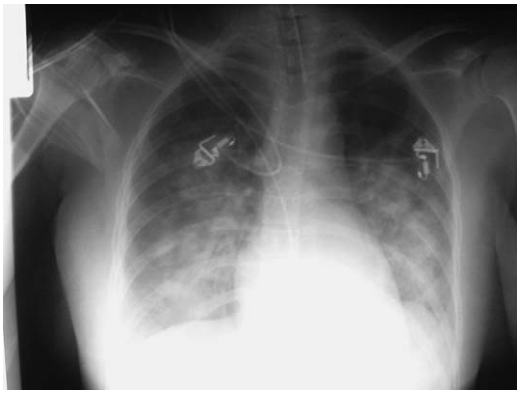

Fig. 5. Radiograph showing alveolar opacities that correspond to pulmonary edema that developed in a young parturient who was exposed to high-dose intravenous β2 receptor agonists. She required short-term mechanical ventilation and improved after discontinuation of the drug and diuretics drugs.

Fig. 6. Radiograph showing acute organizing pneumonia with severe volume loss in a woman who had rheumatoid arthritis who was exposed to penicillamine long-term. The condition is rare. There was no response to penicillamine withdrawal and to corticosteroid therapy and the patient died in a few days on the respirator from intractable respiratory failure.

of rapidly-progressive, dense, diffuse and bilateral alveolar opacities with volume loss [18].

The BAL is indicated and can be performed in nearly all patients if provision is made to correct the hypoxemia that occurs during the procedure [19]. The BAL should be negative for microorganisms and shows elevated $CD4^+$ or $CD8^+$ lymphocyte counts [20]. It is essential to rule out an opportunistic infection, which can be similar to methotrexate lung, with no reliable clinical or radiologic discriminators [11]. *P jiroveci*, cytomegalovirus, *Cryptococcus*, *Herpes zoster*, and *Nocardia* particularly have been associated with treatments with methotrexate in isolated reports, especially if $CD4^+$ lymphocytes are less than 150/μL during treatment or cumulated doses of methotrexate are greater than 700 mg [21]. Parenthetically, such patients are considered for *Pneumocystis* prophylaxis.

The diagnostic criteria of Clearkin et al [22] include an acute onset of dyspnea, temperature greater than 38°C, respiratory rate greater than 28/minute, presence of radiographic abnormalities, a white blood cell count greater than 15,000/μL, negative blood and sputum cultures, a restrictive lung function defect with reduced diffusing capacity, a Pa_{O_2} less than 50 mm Hg on room air, and evidence for ILD on a lung biopsy specimen. The disease is deemed definite, probable, or possible if six, five, or four criteria are fulfilled, respectively.

Histologic findings were available in 49 of the 123 reports that were reviewed by Imokawa et al [23], and included interstitial inflammation or fibro-

sis, granuloma formation, and increased tissue eosinophils in 71%, 59%, 35%, and 18%, of cases, respectively. Although eosinophils are present, they are not a predominant feature. Typically, granulomas are small and ill-defined and central sterile necrosis is unusual. In predominantly granulomatous disease, the involvement is patchy, with intervening areas of normal lung tissue or tissue that shows moderate cellular interstitial pneumonia. Type 2 cell hyperplasia is a notable feature of methotrexate lung, as it is in other forms of chemotherapy-induced lung disease; however, dysplastic changes are less prominent with methotrexate than with other alkylating agents. Alveolar edema, DAD, hyaline membranes, and DAH are unusual features and are seen preferentially in patients who have hyperacute disease [2].

The combination of drug withdrawal and high-dose intravenous corticosteroid therapy usually is associated with a favorable outcome. The chest radiograph and pulmonary functions improve quickly, but complete normalization may take several months. A mortality of 15% in a recent series underlines the need for early recognition and careful management of this condition [7].

Acute eosinophilic pneumonia

Acute eosinophilic pneumonia may be difficult to differentiate from acute methotrexate pneumonitis on imaging (see Fig. 2). Increased numbers of eosinophils in blood or in the BAL are diagnostic of this condition; however, blood or, rarely, BAL eosinophils, may be absent, especially if corticosteroids were given. Drugs that cause acute eosinophilic pneumonia include amitriptyline, chloroquine, fludarabine, infliximab, interleukin-2, minocycline, sertraline, troleandomycin, and tryptophan. There may be overlapping features of this condition with the DI Churg-Strauss syndrome (CSS). Although mechanical ventilation may be required transiently, acute eosinophilic pneumonia generally responds to drug discontinuation and corticosteroid therapy.

Acute chemotherapy lung-diffuse alveolar damage

Acute chemotherapy lung-diffuse alveolar damage (see Fig. 3) is a severe reaction to most chemotherapeutic agents, including antibiotics (bleomycin, mitomycin C), alkylating agents (busulfan, cyclophosphamide, chlorambucil, melphalan), antimetabolites (methotrexate, 6-mercaptopurine, azathioprine, cytosine-arabinoside, gemcitabine, fludarabine), nitrosamines (bischloroethyl nitrosourea [BCNU], chloroethyl-cyclohexyl nitrosourea [CCNU]), and podophyllotoxins (etoposide, paclitaxel, docetaxel) [24]. ATRA, gefitinib, imatinib, irinotecan, interferon-γ, interleukin-2, sirolimus, and TNF-α also can cause the syndrome [2]. Conversely, treatments with chemotherapeutic drugs may require the administration of vast amounts of fluid or cause the vascular leak syndrome. Thus, pulmonary congestion should be ruled out carefully before a specific diagnosis of pulmonary reaction to the particular drug is entertained.

Diffuse alveolar damage is an unusual complication of treatments with noncytotoxic agents [17]. Circumstantial evidence relates DAD and treatments with aspirin, carbamazepine, nitrofurantoin, narcotic analgesics, penicillamine, and simvastatin. DI DAD or chemotherapy lung tend to occur more often and to be more severe in patients who receive multi-agent chemotherapy or in whom radiation therapy or oxygen are given concurrently. Patients who are on a second- or third-line chemotherapy regimen for lung cancer also may be at increased risk. The syndrome manifests with dyspnea, diffuse pulmonary infiltrates, volume loss, and acute respiratory failure that is unresponsive to conventional treatments. Sometimes, DAD complicates a background of previous unresolved drug- or radiation-induced lung damage or fibrosis and occurs as a preterminal event. The density of infiltrates on imaging ranges from diffuse haze or ground-glass to white lungs.

Histopathologic appearances include diffuse alveolar damage with hyaline membranes, dysplasia of type 2 pneumocytes, and interstitial or alveolar edema [4]. The abnormal type 2 cells may be retrieved by BAL [25]. Determining the histopathologic background of ILD in patients who develop severe involvement while receiving chemotherapy is problematic because involvement from the background disease, severe drug- or radiation-induced ILD, pulmonary edema, diffuse alveolar hemorrhage, or an infection can be undistinguishable from DI DAD [11]. Also, patients may be too ill to undergo a confirmatory lung biopsy. Corticosteroid therapy may bring some benefit to patients who have DAD of recent onset. Overall, the response to treatment and the prognosis of this condition when it is related to chemotherapeutic agents are poor.

Acute amiodarone pulmonary toxicity

Acute Am pulmonary toxicity (APT) (see Fig. 4) is an unusual pattern of Am pneumonitis [5,26,27]. The syndrome may occur after a brief period of intravenous drug administration (loading dose), or later into treatment, sometimes after cardiac or pul-

monary surgery or implantation of an automatic defibrillator. Oxygen or mechanical ventilation may synergize APT. In one study, Am was given to patients who had recent lung resection as a prophylaxis for arrhythmias [28]. The study was closed before completion because ARDS developed significantly more often in patients who were treated with Am. Patient who undergo pneumonectomy for lung cancer are at particular risk, because they combine frequent needs for Am in the treatment of postoperative arrhythmias, poor ventilatory reserve due to recent lung resection and, often, a background of smoking, chronic obstructive pulmonary disease (COPD), or emphysema [28]. One study in cardiac surgical patients found no difference in the incidence of pulmonary complications between those who were treated with Am and those who were not [29].

Patients who have acute APT present with diffuse interstitial or alveolar infiltrates, volume loss, and marked hypoxemia. Acute APT must be distinguished from atypical pulmonary edema [30], thromboembolism/infarction, lung cancer, and a coincidental infection. In patients in whom diuresis and appropriate imaging techniques do not enable this distinction, cardiac echography, hemodynamic monitoring, BAL, and a lung biopsy may be required to separate these entities. Histopathologic findings in acute APT include diffuse or resolving DAD, interstitial edema, and fibrosis on a background of more classic changes that suggest APT, such as dyslipidosis with foam cells in alveolar spaces or in the interstitium. The mortality rate in acute APT is 40% to 50%, even if the drug is discontinued and IV corticosteroid therapy is given.

Acute DI pulmonary edema

Acute DI pulmonary edema (see Fig. 5) has been reported during treatments with several chemically-unrelated drugs, including narcotic analgesics, aspirin and other NSAIDs, β-2 agonists, transfusion of blood and products, colchicine, cyclophosphamide, epinephrine, hydrochlorothiazide, methotrexate, nitrofurantoin, noramidopyrine, opiates, quinine, radiographic contrast material, and vasopressin [2,13]. Pulmonary edema also is a complication of overdoses of tricyclic antidepressants or heroin. The attack rate and mechanisms differ between drugs; the most common offenders include aspirin, β-2 agonists, transfusion of blood and products, hydrochlorothiazide, and opiates. Occasionally, pulmonary edema can complicate treatments of pulmonary hypertension with nifedipine, prostacyclin, or nitric oxide. Pulmonary edema has been described during DI anaphylaxis. Pulmonary edema can occur as a complication of fulminant gold or methotrexate pneumonitis [2]. In contrast with other DI ILDs, pulmonary edema can develop shortly (less than 1 minute) after drug administration [31]. DI pulmonary edema also can occur unexpectedly later into treatment with hydrochlorothiazide or aspirin. Pulmonary edema manifests with acute dyspnea and acute respiratory failure or ARDS. Some patients develop a foamy, tracheal exudate that is diagnostic of the condition. Fever, obtundation, and shock are possible associated features. Most cases of DI pulmonary edema are noncardiac and result from a drug-related increase in capillary pulmonary permeability. The normalcy of heart size on chest film, cardiac echocardiography, and pulmonary capillary wedge pressure are in accordance with this theory [13,32]. Histopathologic appearances include the presence of proteinaceous fluid in the alveolar spaces and a near-normal interstitium [4]. Management of DI pulmonary edema includes drug discontinuation and, if needed, positive pressure breathing or mechanical ventilation. Diuretic drugs may influence DI pulmonary edema detrimentally because the combined effect of DI vascular leakage and diuretics may cause severe systemic hypotension. The beneficial role of corticosteroids is unclear. Usually, the pulmonary opacities of pulmonary edema clear quickly. Rechallenge with the drug leads to recurrence and may require repeated hospital admission until the drug etiology is recognized.

DI diffuse alveolar hemorrhage

DI diffuse alveolar hemorrhage (AH; DAH) consists of diffuse and probably synchronous bleeding from pulmonary capillaries, with or without histologically-demonstrable capillaritis [33]. DI DAH can occur in isolation or in association with involvement of the kidney or other internal organs, which suggests DI polyangiitis. Because BAL is an efficient and minimally-invasive diagnostic tool, a lung biopsy rarely has been performed in patients who have the condition. Establishing the responsibility of drugs is problematic, because DAH also can develop in the untreated course of many systemic conditions, including lupus erythematosus, rheumatoid arthritis, mixed connective tissue disease, systemic sclerosis, polymyositis, the antiphospholipid syndrome, Henoch-Schönlein purpura, Behcet's disease, Goodpasture's syndrome, Wegener's granulomatosis (WG), IgA nephropathy, idiopathic glomerulonephritis, myasthenia gravis, cryoglobulinemia, primary antineutrophil cytoplasmic antibodies (ANCA)-positive or -negative micropolyangiitis, and thrombocytopenia [34].

Drugs that cause DAH include abciximab, anticoagulants and fibrinolytics, allopurinol, aspirin, ATRA, azathioprine, clopidogrel, methotrexate, nitrofurantoin, phenytoin, propyl-thiouracil, retinoic acid, sirolimus, tirofiban, and others [2]. Alveolar hemorrhage also can occur as a late complication of bone marrow transplantation. Drugs that cause thrombocytopenia also can produce bleeding in the lung. Occasionally, DAH occurs as a complication of severe pneumonitis from gold, methotrexate, or nitrofurantoin.

Hydralazine, penicillamine, propylthiouracil, and, less often, azathioprine, leflunomide, and phenytoin can produce a pneumo-renal syndrome with severe alveolar hemorrhage that mimics Goodpasture's syndrome or Wegener's disease. Patients who have DAH that results from treatments with these agents may present with a perinuclear (p)-ANCA staining pattern and a antimyeloperoxidase, lactoferrin, or elastase specificity, contrasted with the cytoplasmic ANCA (c-ANCA) staining pattern and antiproteinase 3 (PR3) specificity of naturally-occurring Wegener's disease. Antiglomerular basement membrane (anti-GBM) antibodies rarely are found in DI AH [35], as opposed to naturally-occurring Goodpasture's disease. DAH can be rapidly progressive and requires expeditious management to avoid irreversible respiratory failure by intra-alveolar clotting. Full-blown disease may cause general symptoms, arthralgias, dyspnea, alveolar infiltrates that may assume a bat-wing distribution, and anemia [33]. Hemoptysis is not a constant feature, even in patients who have significant alveolar bleeding and blood loss. An increase in KCO, which suggests free hemoglobin in alveolar spaces, was found in a few patients who had DAH and indicated massive bleeding; however, this is not a consistent or reliable finding. Macroscopically, the BAL demonstrates increased bleeding in sequential aliquots and microscopically, it shows red cells. Hemosiderin-laden macrophages, if present, indicate a background of subacute or chronic bleeding. A search for antinuclear antibodies (ANAs), ANCAs, and anti-GBM autoantibodies is essential in all cases to classify DI DAH (autoimmune versus non-autoimmune) and to separate DI DAH from DAH that is related to a systemic illness. Drug causality is suggested when DAH occurs during treatments with drugs that intentionally produce coagulation defects, although coagulation studies are within an acceptable therapeutic range. Otherwise, causality assessment is more difficult because DAH can occur in so many systemic conditions [34,36]. Patients who present with DAH and ANAs, especially the antidouble–strand DNA subtype, ANCAs with a cytoplasmic staining and PR3 specificity, or anti-GBM antibodies are more likely to have naturally-occurring lupus erythematosus, Wegener's or Goodpasture's disease respectively, rather than a drug condition. A temporal association of drug exposure, p-ANCA titers, and DAH is consistent with the drug etiology. A change in ANCA specificity in a patient who has WG during follow-up may indicate DI disease, rather than relapse of the background condition [37]. Generally, DI DAH does not occur in DI lupus.

Generally, drug therapy withdrawal is advised and may suffice in patients who have anticoagulant-induced bleeding. The role of factor VIIa is not established. Patients who have other forms of DAH and extensive or persistent bleeding, or evidence for renal failure are considered for treatment with corticosteroids or immunosuppressive agents, in a manner similar to autoimmune disease [33]; however, no current guidelines exist.

Acute organizing- or fibrinous OP

Circumstantial evidence relates chronic treatments with Am, nitrofurantoin, and statin drugs to the development of widespread pulmonary infiltrates and respiratory failure that corresponds histologically to acute organizing- or fibrinous OP [38–40] (see Fig. 6). The disease remains unusual; it also can occur sporadically with no identifiable cause. The diagnosis requires a confirmatory lung biopsy. Response to drug therapy withdrawal and corticosteroid therapy is limited; most patients die from the condition [41].

Acute dyspnea with marked pleuritic chest pain

The occurrence of acute dyspnea with marked pleuritic chest pain that coexists with minimal or transient pulmonary opacities on chest imaging (also called "acute DI chest syndrome") (Fig. 7) was reported in close temporal association with treatments with ATG, bleomycin, crack cocaine, cyclophosphamide, hydrochlorothiazide, IVIG, methotrexate, minocycline, nitrofurantoin, statins and triptans; in patients who had DI lupus; or in association with neutrophil crisis following the administration of granulocyte or granulocyte-macrophage CSFs. The complication also can occur after sclerotherapy of esophageal varices or closure of brain arteriovenous malformations with acrylate. Generally, patients who have this syndrome are admitted to the emergency department for acute chest pain and dyspnea that suggests pulmonary embolism, pericarditis, or myocardial infarction. The histopathologic background of

Fig. 7. Radiograph showing a young woman who was exposed to minocycline and developed subacute/chronic drug-induced infiltrative lung disease corresponding to eosinophilic pneumonia. This was associated with acute chest pain and minimal radiographic shadowing.

Fig. 8. Radiograph showing diffuse ILD secondary to chronic exposure to carbamazepine. Despite the presence of extensive pulmonary infiltrates, there was little impact of pulmonary functions during the first few days of observation. The drug was not recognized as the cause of the pulmonary infiltrates. The condition deteriorated and culminated in ARF. The patient improved after drug withdrawal and corticosteroid therapy. (Courtesy of S. Lacroix, MD, Périgueux, France.)

this condition is unclear; however, evidence for ILD, pulmonary edema, and angiitis was obtained in a limited number of cases. Withdrawal of the suspected medicine is followed by rapid reversal of symptoms that return quickly if the patient is rechallenged.

Subacute/chronic drug-induced infiltrative lung disease

All the aforementioned patterns of DI-ILD can exist in a diminutive form in patients in whom the diagnosis of the drug condition is raised in time and the drug is discontinued early, or if the reaction is quenched by corticosteroid therapy. Some drugs or drug reactions, however, intrinsically produce milder reactions than those that were described above.

Most cases of DI NSIP have a benign course (see Fig. 8, Fig. 9) with dyspnea, a dry cough, moderate fever, pulmonary infiltrates and, sometimes, a skin rash, or changes in liver chemistry that denote concomitant hepatotoxicity. Many drugs can cause this syndrome [17], including ACEI, β-blockers, intracavitary BCG therapy, chlorambucil, chrysotherapy, flecainide, fludarabine, fluoxetine, maprotiline, nitrofurantoin, nilutamide, procainamide, simvastatin, and sulfasalazine [2]. Mild methotrexate lung is less common than is the acute form of the disease. Radiographic studies indicate bilateral, symmetric, interstitial or alveolar infiltrates. A miliary pattern was reported with the use of BCG, chrysotherapy, methotrexate, nilutamide, and sirolimus. The infiltrates tend to localize in the lung bases or mid-lung zones, rather than specifically in the apices, or can be diffuse. Studies in a series of patients who presented with NSIP that was due to the same drug showed that the pulmonary opacities can localize almost anywhere in the lung [42]. The radiographic density can be discrete haze or ground-glass or scattered areas of dense alveolar consolidation (see Fig. 8). Blunting of costophrenic angles, pleural effusion, and mediastinal lymphadenopathy are occasional findings. On HRCT, interstitial septal lines, areas of increased attenuation, a ground-glass pattern, crazy-

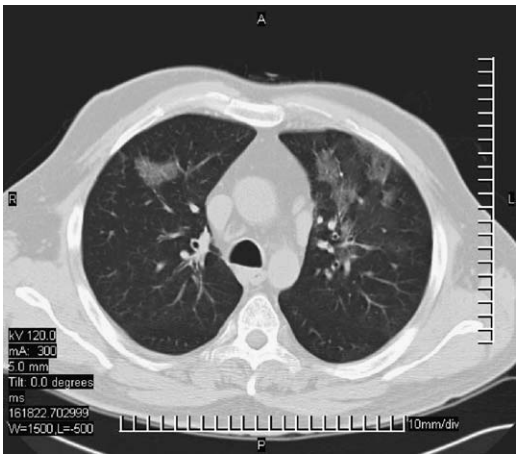

Fig. 9. HRCT scan in a patient who had asymptomatic pulmonary infiltrates during treatment with fluoxetine. The infiltrates cleared after drug discontinuance. (Courtesy of C. Parouty, MD, Brive-la-Gaillarde, France.)

paving, or a mosaic pattern can be present (see Fig. 9). Restrictive pulmonary functions and hypoxemia usually are present and these roughly correlate with the extent of involvement on imaging [43]. In azathioprine pneumonitis, however, restrictive physiology and hypoxemia may coexist with mild radiographic changes. Generally, the BAL is indicated to exclude an infection and to support the drug etiology [25]. In DI NSIP, the BAL shows a lymphocyte predominance with increases in $CD4^+$ or $CD8^+$ subsets [20,25]. Neutrophilic, mixed lymphocytic and neutrophilic, or eosinophilic patterns also were reported [42]. A lung biopsy is required rarely to confirm the diagnosis because most cases have a mild course and respond to drug therapy withdrawal and the histopathologic appearances have been described in the past [4]. A risk-benefit analysis of transbronchial or video-assisted lung biopsy versus conservative management is not available. The main histologic features include cellular NSIP, interstitial edema, and, sometimes, areas of OP or fibrosis [4,23]. Overall, the prognosis of DI NSIP is good. Corticosteroid therapy is indicated in patients who have extensive opacities, significant hypoxemia (see Fig. 8), or in those in whom drug therapy withdrawal does not translate into improvement. The development of lung fibrosis following recognition and treatment of this problem is unusual. Rechallenge with the drug often leads to relapse with increased severity [7]; proper instructions should be given to avoid inadvertent rechallenge. In a few patients the distinctive pattern of desquamative interstitial pneumonia is identified on lung biopsy. When it is related to drugs, this pattern suggests exposure to nitrofurantoin or interferon [2,44].

DI PIE, also known as eosinophilic pneumonia (Fig. 10), can be caused by multiple chemically-unrelated drugs, including ACEI, antidepressants (amitriptyline, clomipramine, maprotiline, sertraline, trazodone, venlafaxine), aspirin and other NSAIDs, carbamazepine, chloroquine, interferon, mesalazine, minocycline, inhaled or parenteral pentamidine, phenytoin, pyrimethamine, radiographic contrast material, sulfamides (sulfasalazine, sulfamethoxazole), and L-tryptophan, a now recalled dietary supplement [2,45]. Recently, cyclooxygenase-2 inhibitors and infliximab also were implicated. Certain drug classes (eg, antibiotics, antidepressants, ACEI, NSAIDs) collectively cause PIE [46]. Methotrexate lung often is associated with mild eosinophilia in the blood, BAL, and lung tissue; however it is not an eosinophilic pneumonia. A few patients who have PIE exhibit clinical features that overlap with the CSS; distinguishing the two conditions can be problematic. A few drugs,

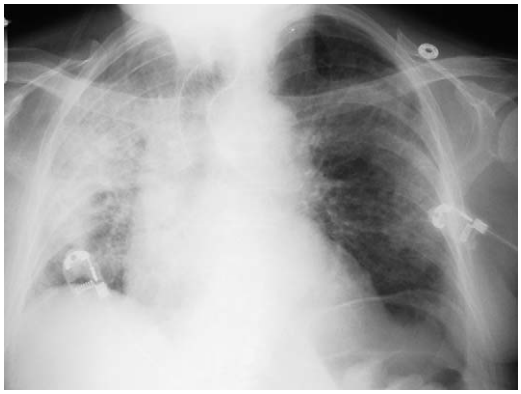

Fig. 10. Eosinophilic pneumonia during exposure to an angiotensin-converting-enzyme inhibitor. The condition generally is benign. The opacities of eosinophilic pneumonia characteristically localize in the apices, but may localize elsewhere in the lung or be asymmetric.

mainly leukotriene receptor antagonists, can produce both conditions [2]. The possibility of a parasitic infection should be considered in any patient who has PIE, because this requires specific management.

Typically, PIE develops during oral or parenteral treatments with the causative drug. Rarely does the condition develop after termination of treatment or after radiation therapy [47]. Drugs administered topically, or via inhalation also may cause PIE. Risk factors for PIE include previous atopy or asthma; a history of allergic reactions to other or related drugs; and repeated courses of treatment with the drug, which can sensitize patients [48]. Onset is difficult to predict; for instance, NSAIDs-induced PIE develops after 1 week to 3 years (average 17 weeks) into treatment [46].

Typical signs and symptoms of PIE include dyspnea, a dry cough, fever, chest discomfort, and a skin rash. The intensity of respiratory symptoms and of hypoxemia correlate with the extent of pulmonary infiltrates. Symptoms are more prominent if an eosinophilic bronchitis is present; this is suspected if wheezing is audible. Systemic symptoms can be present in patients who have elevated levels of blood eosinophils. An eosinophilic pleural effusion [49] and involvement of distant organs were described in a few patients.

The pulmonary infiltrates of PIE typically are alveolar and symmetric [45]. The pattern of apical, peripheral subpleural opacities, coined the "photographic negative of pulmonary edema," is distinctive but it is found in less than half of the cases of DI eosinophilic pneumonia. The opacities of PIE may be

diffuse, causing respiratory impairment, or migratory, or may appear as faint shadowing or discrete ground-glass. Kerley "B" lines have been described consistently in PIE that is due to NSAIDs or other drugs [46]. It may be difficult to distinguish PIE from NSIP on the plain chest radiograph. On HRCT, the opacities of PIE range in density from a discrete haze, to patchy subpleural shadowing and diffuse consolidation. Enlargement of mediastinal lymph nodes is an occasional finding in PIE that is associated with exposure to minocycline or certain NSAIDs. The presence of pleural effusion characterizes those cases with severe involvement [49].

PIE is diagnosed by the presence of increased numbers of eosinophils in blood—which can be as high as 80%—BAL, or lung tissue [45]. Peripheral eosinophilia can be suppressed transiently if corticosteroids are given. IgE levels may be increased in serum. The BAL commonly shows an increase in eosinophils and, often, in lymphocytes. A lung biopsy is required rarely for diagnosis, except if blood and BAL eosinophilia is lacking. On histology, an interstitial infiltrate of eosinophils admixed with mononuclear cells is seen. A Giemsa stain may help to identify the eosinophils. Foci of OP may be present and generally are inconspicuous. Some patients, however, present with overlapping features of the two conditions; separating OP from PIE may be problematic. Eosinophils may cluster around arterioles without invading their walls. An active vasculitis raises the suspicion of the CSS.

Generally, relating PIE to drug exposure is straightforward if definite blood or BAL eosinophilia is present, if patients are exposed to one eligible drug, and if drug withdrawal is followed by improvement of symptoms and imaging. Drug withdrawal may not translate into immediate improvement in patients who have extensive involvement; they may require corticosteroids therapy, which generally, quickly reverses all manifestations of PIE [45]. It is not unusual for mild subclinical blood eosinophilia to persist for a few weeks or months after drug withdrawal. Death in PIE is the exception.

Rechallenge with the causative medicine leads to recurrence of the clinical manifestations of PIE, blood and BAL eosinophilia, and pulmonary infiltrates. According to the literature, rechallenge carries little risk because constitutional symptoms and increased blood eosinophilia act as early markers of relapse. All cases with rechallenge may not have been published and caution is required, inasmuch as the diagnostic contribution of rechallenge is questionable. Patients who have inflammatory bowel disease who develop PIE as a result of exposure to sulfasalazine or mesalazine can be rechallenged deliberately with incremental doses of the drug [50]. This has resulted in desensitization, reinstatement of the drug, and maintained control of the basic disease. Patients who relapse after graded rechallenge can be rechallenged again using smaller doses of the drug to achieve successful desensitization.

Amiodarone pneumonitis-amiodarone pulmonary toxicity

Am is a antiarrhythmic benzofuran drug with an imposing adverse effect profile. APT was first recognized in the early 1980s in the United States. During chronic treatment, Am and its main metabolite, desethylamiodarone (DEAm), accumulate extensively in organs and achieve toxic concentrations in tissues. Two molecules of iodine are present for each molecule of Am or DEAm. Am and DEAm interfere with the catabolism of lung phospholipids, which also accumulate in lung. Am and DEAm efflux slowly from tissues after treatment discontinuation. These pharmacokinetic properties account for the many of the distinctive clinical (slow onset and improvement, possible onset of APT after termination of treatment, relapse late after drug withdrawal), imaging (high CT numbers of opacities on HRCT), and pathologic (dyslipidosis present in lung cells, particularly alveolar macrophages which accumulate in alveolar spaces) characteristics of APT [5].

The prevalence of Am pneumonitis varies from 0.1% in patients who are on a low dosage to 50% in patients who receive elevated (eg, 1200 mg/day) dosages. On average, APT develops in 5% to 15% of patients who take at least 500 mg/day of Am, versus 0.1% to 0.5% in those who are treated with up to 200 mg/day [51,52]. Placebo-controlled studies that used low-dosage regimens of Am decreased the incidence of APT to a still considerable 1.6% more than the rate of ILD in the placebo group [51]. APT remains a common occurrence in patients and the severity of this condition has not changed substantially with time.

The onset of APT is unpredictable and it is insidious [53]. In a few patients, APT develops acutely over a few days. Generally, APT develops after a few weeks and up to several years into treatment. Early onset after a few days of treatment is unusual; high-loading doses of Am may increase the risk of early APT. APT may develop after the dosage of Am is augmented. On average, APT develops after 18 to 24 months into treatment and is diagnosed approximately 2 months after the onset

of clinical symptoms (Fig. 11). This leaves room for earlier diagnosis. A subclinical increase in the erythrocyte sedimentation rate or faint pulmonary infiltrates may precede the clinical onset of APT. Clinically overt APT manifests with dyspnea; a dry nonproductive cough; weight loss; malaise; and moderate fever. The dyspnea may be exaggerated if Am-induced hyperthyroid state is present in association. Crackles are a common finding and a friction rub is present in a few patients. Sometimes, a pleuritic chest pain is present. Leukocytosis and an increase in circulating lactate dehydrogenase levels are common findings; the latter can precede the clinical onset of APT. Increased circulating levels of surfactant-associated protein D have been reported. The role of serum brain natriuretic peptide levels in distinguishing APT from left ventricular failure remains imprecise [53]; patients may present with APT that is superimposed on a background of left ventricular dysfunction. Adverse effects of Am in liver or thyroid are present occasionally in association with the pulmonary toxicity; appropriate tests are required to detect these complications.

The imaging patterns of APT are extremely varied and it is easy to be misled [53–56]. APT is a disease of the alveolar or interstitial compartments. Thus, APT is characterized by alveolar, interstitial, or mixed alveolar–interstitial shadows. The radiographic appearances include bilateral, often asymmetric, interstitial or alveolar infiltrates that may involve all areas of the lung fields, including the apices. Generally, a moderate loss of volume is present in patients who have diffuse opacities. The opacities of APT may assume a recognizable lobar distribution. Inexplicably, there is an impression that the right lung (mainly the right upper lobe) is more frequently or more densely involved than the left [53–56]. Some patients present with apparently unilateral involve-

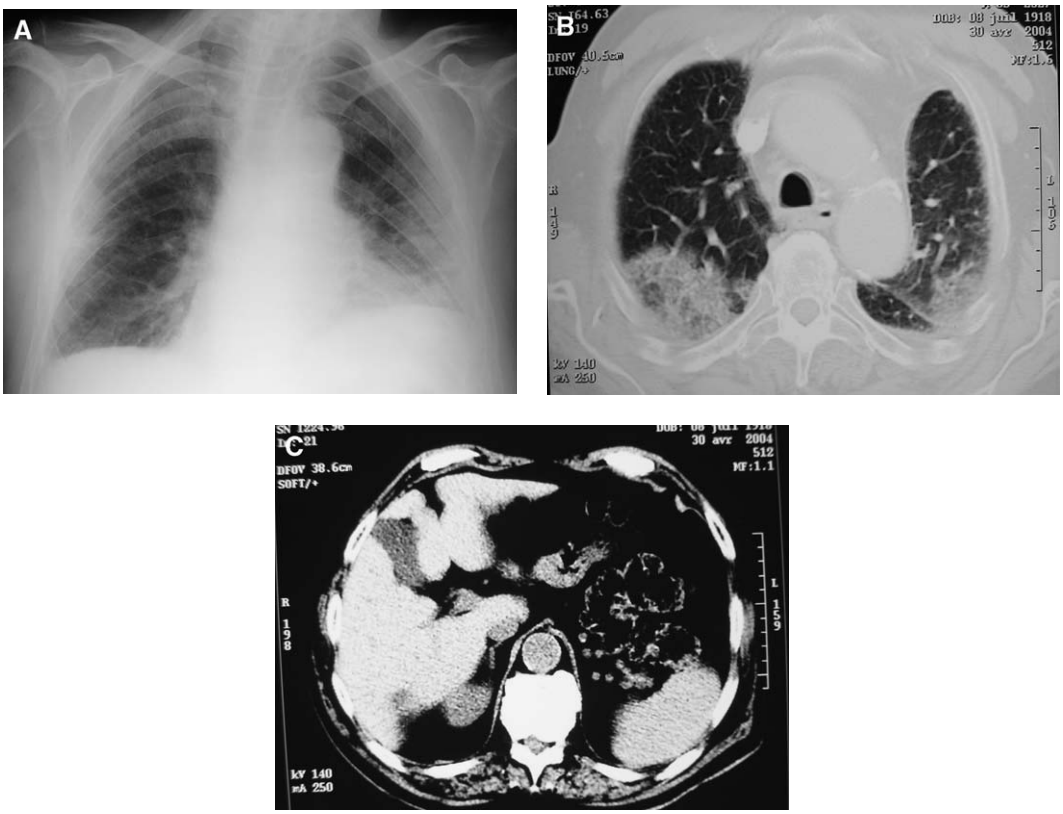

Fig. 11. (*A*) Radiograph showing APT in an elderly man. (*B*) The CT is more sensitive to detect minute foci of APT. Pulmonary infiltrates often are asymmetric on CT and may display high CT numbers. The diagnosis of APT was suggested by the absence of other explanations for the pulmonary infiltrates. (*C*) High-attenuation numbers of the liver on contrast unenhanced CT suggested amiodarone exposure, not toxicity. (Courtesy of A. Fanton, MD, Dijon, France.)

ment. Other patterns of APT include a lone or multiple subpleural mass or masses. The masses abut the pleura can be thickened and occasionally there is pleuritic chest pain. The masses can mimic pulmonary infarction, infectious or OP, and peripheral lung carcinoma or lymphoma. APT presents rarely in the form of multiple shaggy nodules that sometimes are surrounded by a halo that corresponds to attenuated Am pneumonitis peripherally, or of large biapical nodules.

On HRCT, the involvement often is patchy and asymmetric, with areas of haze, ground glass, intralobular linear opacities, alveolar shadowing, or dense consolidation or masses with high attenuation numbers. Pleural thickening is a common finding in the areas of parenchymal involvement. Although the chest radiograph indicates unilateral disease, the HRCT often indicates bilateral disease [57]. In a study of 20 patients who had mild APT [54], all patients had ground-glass opacities, areas of consolidation were found in 4 patients, and intralobular reticulations were noted in 5 patients. A subpleural distribution of the opacities was more common (n = 18) than a central distribution (n = 2). High density in the area of APT was present in 8 patients. In more advanced disease, increased attenuation seems to be a more consistent feature of APT [58]. Large nodules that correspond to APT may exhibit a central area of decreased attenuation [59]. The impression is that all patients who have APT have distinct patterns of involvement on imaging. Occasionally, an exudative pleural effusion is present in association with the pulmonary disease. APT may produce attenuated changes on imaging in patients who have COPD or emphysema, in whom for a given amount of lung shadowing, the impact on gas exchange is more severe.

Generally, a restrictive lung dysfunction, decreased KCO, and arterial hypoxemia are present in APT; these changes are more severe in patients who have extensive disease. Interpretation of pulmonary function tests (PFT) is against the background of COPD, or restrictive lung dysfunction from chronic left ventricular dysfunction, two commonly present conditions in such patients. Baseline PFTs should be obtained in patients who receive Am long-term, to which further changes can be compared, should pulmonary infiltrates develop. The earliest abnormality in APT is a consistent and precipitous decrease in KCO. Left heart failure does not alter this test significantly. An isolated decrease of KCO does not necessarily indicate clinically recognizable disease because overt APT will develop in a third of such patients. Accordingly, an isolated reduction of KCO should not prompt discontinuation of Am because this carries an intrinsic risk of recurrence of the arrhythmia, unless there is clinical or imaging evidence for disease. Repeated measurement of this parameter is indicated. Conversely, a stable diffusing capacity indicates the lack of clinically meaningful APT.

The contribution of BAL to the diagnosis of APT is controversial. A wide range of abnormalities can be found in the BAL in Am pneumonitis, including an increase in neutrophils, lymphocytes, or both, or even a normal distribution [60]. Patients who have lymphocytosis in the BAL have a shorter time to onset of the pneumonitis. Eosinophilia as an isolated finding in BAL is an unusual feature. The presence of foam cells with lamellar inclusions on microscopic or electron microscopic examination of BAL of patients who are exposed chronically to Am is a routine finding and does not indicate toxicity [61]. In the absence of foam cells, the diagnosis of classic APT is considered unlikely. There are no consistent data on the BAL pattern of patients who have Am-induced ARDS or fibrosis. Hemosiderin-laden macrophages have been described in the BAL in a few patients who had Am pneumonitis; this may be related to left ventricular failure.

APT is mainly a diagnosis of exclusion. The lung biopsy is performed rarely because patients often deteriorate after the procedure [53], and a risk benefit is not available. In patients in whom there is no substitute for Am or heart transplantation is planned, the diagnosis of APT must be secured quickly and a lung biopsy may be justified. In other patients, it is reasonable to avoid the recourse to lung biopsy, to narrow down diagnostic possibilities by noninvasive tests, and to proceed with drug therapy withdrawal and corticosteroid therapy. The histopathologic appearances of APT include [4,5] septal thickening, interstitial edema, nonspecific inflammation, fibrosis, and the presence of lipids within interstitial and endothelial cells and lying free in alveolar spaces. Many free foamy alveolar macrophages support the diagnosis of APT. These cells may be so numerous as to mimic desquamative interstitial pneumonia. Other findings include OP or fibrinous and OP [40] (see later discussion), hyperplasia of type II cells, and interstitial fibrosis. Active or resolving DAD and hyaline membranes characterize those cases with acute respiratory failure.

Corticosteroids positively influence the outcome of APT. If indicated, corticosteroids should be given for months and tapered prudently, otherwise APT may recur owing to the persistence of Am in lung. A relapse of APT may prove to be much more difficult to control than the first bout of the disease.

Overall, the mortality is less than 10% in ambulatory patients; however, it is higher (20%–33%) in patients who require admission to the hospital.

Because of its prevalence, there are questions about the early detection of APT. According to Stelfox et al [52], baseline chest radiograph and PFTs should be performed before Am is initiated. Although follow-up surveillance with chest radiograph and PFT at 3- to 6-month intervals has been recommended, pulmonary toxicity can develop rapidly and radiographic abnormalities may not precede clinical toxicity. Repeat lung function testing should be reserved for patients who develop new symptoms or chest radiograph findings. Patient self-reporting of symptoms and regular clinical evaluation are encouraged, and are likely the easiest and most useful strategies for prompt detection of APT.

Organizing pneumonia or bronchiolitis obliterans organizing pneumonia

DI OP/bronchiolitis obliterans organizing pneumonia (BOOP) is a distinctive pattern of lung response to drugs that is characterized by alveolar fibrosis as the dominant histopathologic feature [39]. OP has many causes other than drugs [62], however, which makes evaluation of drug causality difficult. DI OP was reported initially as a severe and often fatal lung disease in patients who were treated with the early antihypertensive drugs, hexamethonium and mecamylamine [2]. After these drugs were recalled, DI OP almost fell into oblivion. OP that simulated pulmonary metastases on HRCT was described during treatments with bleomycin [63]. Eventually, Am, β-blocking agents, carbamazepine, ergolines, gold, group-I interferons, methotrexate, minocycline, nitrofurantoin, penicillamine, sulindac, and radiation therapy to the breast were recognized to produce an OP pattern [2,39]. Circumstantial evidence relates OP to treatments with ACEI, NSAIDs 3-hydroxy-3-methyl glutaryl-coenzyme-A reductase inhibitors (statins), and other drugs [2,39].

Clinically, DI OP manifests with dyspnea, low-grade fever and, sometimes, lancinating or acute pleuritic chest pain. Several imaging patterns are recognized. Typically, the disease is suspected when migratory opacities are seen on chest films that are taken sequentially over a few weeks or months [64]. Inexplicably, there may be intervening periods with a normal chest radiograph, despite continued exposure to the drug. In other cases, the opacities are in the form of a lone mass or flocculent masses or have a recognizable segmental or lobar distribution and contain air bronchograms. The opacities also may appear as patchy or stellate shadows along the bronchovascular bundles; this pattern is suggestive of OP that is related to nitrofurantoin [65] and, possibly, penicillamine. Other patterns of DI OP include multiple shaggy nodules (with the use of bleomycin, carbamazepine, minocycline, or statins), biapical masses (with the use of mesalazine, or sulfasalazine), and diffuse infiltrates (with the use of nitrofurantoin) [39].

A distinctive BAL pattern has yet to be described in association with DI OP. Often, however, the percentage of lymphocytes and sometimes of neutrophils or eosinophils is increased [25]. If a lung biopsy is deemed necessary to establish a reliable diagnosis, the video-assisted surgical approach is preferred to the transbronchial route because areas of OP can be an incidental finding on a biopsy of small size. Histology reveals interstitial inflammation and alveolar collapse superimposed on the dominant background of alveolar and ductal fibrosis. In patients who have Am-induced OP, changes that are suggestive of APT can be present in association with the dominant pattern of OP. In a fraction of patients, significant tissue eosinophilia is present as an associated feature, which makes the differentiation of organizing from eosinophilic pneumonia difficult. Acute fibrinous OP (AFOP) is a recently recognized entity [40]. AFOP shares some features with (including exposure to drugs), but has a more severe course than, classic OP [40]. On histology in AFOP, there is the dominant pattern of intra-alveolar fibrin and OP that is associated with varying amounts of hyperplasia of type 2 pneumocytes, interstitial edema, and a background of acute or chronic inflammation.

Distinguishing OP that is due to drugs from that due to a background disease can be problematic because the condition has been described in association with multiple connective tissue disease (CTD) and inflammatory diseases, such as polymyalgia rheumatica, inflammatory bowel disease, and other conditions [34]. If patients have moderate symptoms, drug discontinuance is justified and follow-up indicates if symptoms of OP abate which supports the drug etiology.

Not all patients who have migratory pulmonary opacities and a background of compatible exposure to drugs actually have OP; the same imaging pattern can be seen in patients who have DI PIE and BAL may not separate the two conditions well. In patients who have mild symptoms, the risk of lung biopsy may not be justified; the patient may be observed after drug withdrawal, which serves as a diagnostic test. Disappearance of symptoms and pulmonary opacities supports the drug etiology, although the histopathologic

background remains unclear. If drug discontinuance is not followed by improvement within a few weeks, then a lung biopsy or a trial of steroids should be considered.

Multiple relapses of DI OP can occur that require repeated courses or augmented dosage of corticosteroids when the drug condition is not recognized and the drug is continued. The OP that is associated with Am may relapse even if the drug was withdrawn several weeks earlier, especially during steroid tapering. Prolonged use, augmented dosage, or reinstatement of corticosteroid therapy is indicated [5].

DI pulmonary fibrosis (Fig. 12) can develop during or after treatments with Am, chemotherapeutic agents (particularly cyclophosphamide and the nitrosoureas, BCNU and CCNU), gold, methotrexate and, possibly, sulfasalazine [2]. Because pulmonary fibrosis also can occur sporadically and in the course of connective tissue disease, it may be difficult to assess drug causality, unless there is a close temporal association between drug exposure and the development of pulmonary fibrosis. Thus, all chest radiographs that are taken before treatment should be reviewed. DI pulmonary fibrosis can develop during treatment with the drug (eg, with Am) or later, up to several years after termination of treatment (eg, with Am, cyclophosphamide, nitrosoureas, or radiation therapy). DI pulmonary fibrosis manifests with predominantly basilar streaky opacities and volume loss. Honeycombing and clubbing are unusual or late features. On HRCT, there are coarse, interstitial reticular and perilobular opacities and traction bronchiectasis that predominate at the lung bases.

Am-induced fibrosis can develop in 5% to 7% of patients who develop an episode of classic Am pneumonitis, or as a de novo phenomenon [5]. Criteria for the diagnosis of Am-induced fibrosis include a normal chest radiograph before institution of treatment with Am, development of fibrosis during or shortly after termination of treatment, the impression

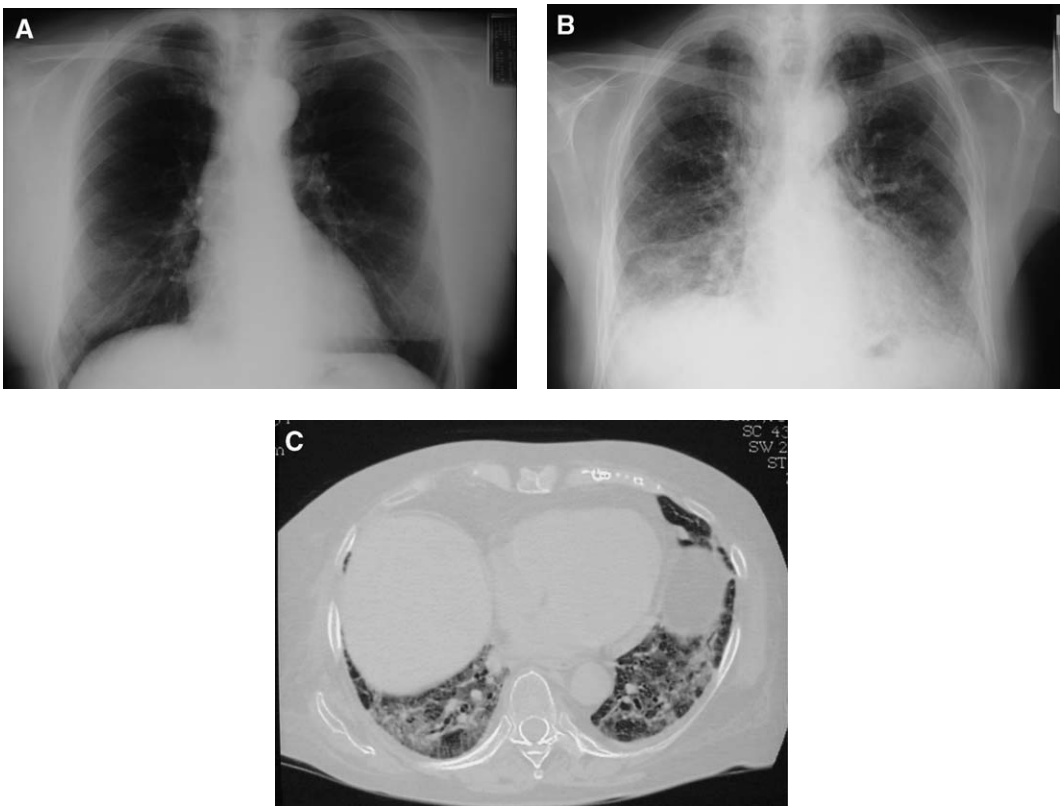

Fig. 12. (*A*) A normal chest film before institution of treatment with amiodarone is suggestive. (*B*) Radiograph showing drug-induced pulmonary fibrosis that developed in a 75-year-old man after a few months of exposure to amiodarone. (*C*) Honeycombing is an unusual or late feature of drug-induced fibrosis. This patient died after a few months from debilitating respiratory failure. (Courtesy of P. Ravier, MD, Dijon, France.)

of a more rapid progression with time as compared with idiopathic pulmonary fibrosis, the absence of other causes for the fibrosis, and sometimes, the notion of previous APT with sluggish or incomplete resolution. The histopathologic features of Am-induced fibrosis are those of severe interstitial fibrosis, with thickened alveolar septa and type II cell dysplasia. Late changes include honeycombing. Features of Am toxicity can be present in Am-induced fibrosis, depending on the time from biopsy to discontinuation of the drug. The prognosis of Am-induced fibrosis seems to be poorer than that of fibrotic NSIP or usual interstitial pneumonitis. Whether a history of past exposure to Am is a risk factor for "idiopathic" pulmonary fibrosis later in life is conjectural [9].

A peculiar pattern of pleuropulmonary fibrosis can be observed in adults after the administration of carmustine, cyclophosphamide, or multi-agent chemotherapy regimens, notably in early childhood. The features are a pattern of upper-lobe fibrosis that involves the upper and lateral aspects of the lung; sometimes, the pleura also is involved and mimics late radiation injury to the chest [66–68]. In children, there is progressive narrowing of the anteroposterior diameter of the thorax, which contributes to the restrictive physiology later in life [69]. Clinically, dyspnea and, sometimes, marked chest pain and a friction rub are present. Although not many cases are available for review, the prognosis of this condition is poor with lack of response to corticosteroid therapy and 50% mortality [67].

In addition to chronic respiratory insufficiency, patients who have DI fibrosis, especially if induced by chemotherapeutic agents, may suffer repeated episodes of pneumothorax that are difficult to treat as lung expansion is compromised. This further aggravates lung function. Rarely, drug withdrawal is followed by measurable benefit in DI fibrosis. The response to corticosteroids is unpredictable and often is limited in magnitude or duration. Lung transplantation is an option in a few patients.

Infiltrative lung disease related to drug- or radiation-induced vascular injury

The use of leukotriene receptor antagonists (LTRA) in the treatment of asthma recently was associated with the development of the CSS [2]. Patients present with peripheral eosinophilia, diffuse pulmonary infiltrates, rarely DAH, in the context of suggestive extrapulmonary involvement (cardiomyopathy, muscle pain, mononeuritis and, less often, digestive or dermatologic changes). Symptoms occur a few weeks or months into treatment with the LTRA. Corticosteroid tapering may trigger the onset of CSS in some patients. As for any novel adverse effect, a reporting bias cannot be excluded. The classic pathologic findings in the lung in naturally-occurring CSS include a combination of eosinophilic pneumonia, granulomatous inflammation, and vasculitis. There is no specific description of the histopathologic appearances in DI CSS. Some evidence relates treatments with macrolides, aspirin, vaccination against hepatitis B and immunotherapy to the development of CSS [2].

Overspill of microspheres that contain therapeutic doses of ^{131}I or ^{90}Y that were administered by way of the intravenous or hepatic arterial route to treat thyroid or hepatocellular carcinoma may expose the lung to considerable irradiation. Transient or irreversible changes develop in 5% to 10% of patients after one or more treatment courses. Early disease is in the form of pulmonary infiltrates and progressive respiratory failure or ARDS. Late changes appear on CT in the form of symmetric, "parachute-like" opacities at a distance from the pleura and the hili. The prognosis of both forms is poor [70].

DI veno-occlusive disease has a low prevalence. It refers to diffuse fibrous obliteration of pulmonary venules. This entity was reported in oncology patients following the use of bleomycin, carmustine, gemcitabine, mitomycin, vinca alkaloids, or radiotherapy, and in recipients of bone marrow transplant. Veno-occlusive disease may appear in patients who have malignancies before any form of treatment. Patients present with dyspnea, ill-defined interstitial markings and Kerley "B" lines. Postcapillary pulmonary hypertension and right heart failure eventually develop. The contribution of drugs, radiation therapy, or transplantation versus the underlying malignancy or a chance association is unclear.

Other forms of involvement of the pulmonary circulation that may produce pulmonary infiltrates include:

- Endogenous fat embolism, which occurs in a fraction of patients shortly after liposuction [71]. Symptoms include chest pain and transient pulmonary infiltrates a few hours after the procedure. The disease often is self-limited.
- Total parenteral nutrition and drugs that are dissolved in lipids (eg, propofol) can cause exogenous fat embolism [2]. In patients who have ARDS, total parenteral nutrition produces deterioration in gas exchange, a neutrophilic alveolitis, and changes in the lipid profile of the BAL fluid [72].

- Stem cell or bone marrow transplant recipients may present with pulmonary nodules a few months after engraftment. These nodules may correspond to pulmonary cytolytic thrombi. Histologic studies indicate sterile necrotic aggregates of leukocytes and disrupted endothelium [73]. Careful exclusion of an infection, particularly with *Aspergillus* spp, is required [73].

Exogenous lipoid pneumonia

Exogenous lipoid pneumonia (Fig. 13) is a complication of chronic exposure to mineral oil. Classically, contamination occurs during long-term ingestion of paraffin at night to combat constipation [74]. Less common exposures include inhalation of lipid formulation of amphotericin B and cyclosporin, application of mineral oil in the nasal cavity or on the face, the compulsive use of lipsticks, application of oily material on chest wounds, repeated use of oil-containing eyedrops [75], suicide attempts with a lipid formulation and, rarely, inhalation of WD-40 or self-injection of lamp oil [76]. Patients who have swallowing difficulties or achalasia and the elderly are at risk. Spreading or aspiration of oil leads to alveolar filling and an interstitial reaction, and later develops into pulmonary fibrosis. Lipoid pneumonia may manifest as predominantly basilar or diffuse opacities [74], a solitary mass (called paraffinoma), or multiple lobulated masses or nodules. On HRCT, mild or extensive alveolar filling and a crazy paving pattern have been described [77]. The opacities demonstrate low attenuation and often stay at a distance from the pleural surface [74]. The lung vasculature may be visible spontaneously within the areas of parenchymal involvement on contrast nonenhanced CT [74]. Commonly, the BAL has a milky or oily appearance and lymphocytic or neutrophilic alveolitis can be present. Ideally, the diagnosis is suggested at history taking and is confirmed by the finding of free lipid in BAL fluid or lipid vacuoles in alveolar cells that are retrieved in sputum or BAL [74]. Mineral oil stains positive with Oil-red–0 and Sudan black [74]. The presence of mineral lipids can be confirmed by chromatography/mass spectrometry of BAL fluid or lung tissue; rarely, a lung biopsy is justified. The disease often is missed at history taking. In about 50% of patients in one series, the diagnosis was established in retrospect on the lung biopsy [78]. Histopathologic appearances include alveolar filling by Oil-red–0 and Sudan black–stainable lipids. The histopathologic appearances and staining pattern usually enable the distinction of exogenous lipoid pneumonia with Am pneumonitis and lipid storage diseases. Patients often do not improve significantly after drug withdrawal. Corticosteroid therapy offers little benefit. The outcome is unpredictable and seems to be poorer in the elderly. Patients may suffer recurrent bouts of bronchopneumonia or superinfection with atypical mycobacteria or *Aspergillus* spp or the development of lung cancer.

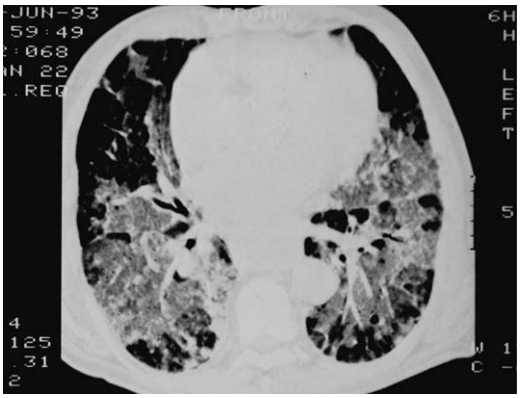

Fig. 13. HRCT showing exogenous lipoid pneumonia. (Courtesy of J.C. Dalphin, MD, Besançon, France.)

The occurrence of basilar pulmonary infiltrates secondary to silent aspiration of kayexalate or psyllium has been reported.

Drug-induced sarcoidosis

Most cases of DI sarcoidosis (not just granulomas) are associated with treatments with IFN-α or -β or pegylated IFN, whether or not ribavirin is combined with IFN in the treatment of hepatitis C infection [79]. IFN-induced sarcoidosis develops after a few months into treatment. Rarely, sarcoidosis develops after withdrawal of IFN. IFN can produce a relapse of previously-diagnosed sarcoidosis. Patients may complain of fatigue, breathlessness, or cough; these manifestations can be obscured by the flulike symptoms that usually accompany the first weeks of treatment with IFN. IFN-induced sarcoidosis reproduces naturally-occurring sarcoidosis, with involvement of mediastinal lymph nodes, lung, skin (including erythema nodosum and Löfgren syndrome), liver, central nervous system, kidney, and abnormal calcium homeostasis. Lymphocytes are increased in the BAL. The diagnosis of IFN-induced sarcoidosis is established by the demonstration of

noncaseating granulomas in lung, bronchial mucosa, mediastinal lymph nodes, or other organs. IFN-induced sarcoidosis is improved with reduction in drug dosage, drug withdrawal, or institution of corticosteroid therapy. Thoracic and other manifestations of IFN-induced sarcoidosis tend to disappear in a few months. In some patients, the granulomatous process may progress with time, despite drug therapy withdrawal; corticosteroids are required as an adjunctive therapy. No patient who had IFN-induced sarcoidosis has yet progressed to the late pulmonary fibrotic stage that is seen in naturally-occurring sarcoidosis.

Granulomas, not sarcoidosis, are occasional findings in lung or in lymph nodes of patients who are exposed to etanercept, methotrexate, phenylbutazone, phenytoin, and sirolimus [2].

Drug hypersensitivity syndrome

Drug hypersensitivity syndrome (DHS) is an idiosyncratic reaction that is defined by the clinical triad of fever, rash, and such organ involvement as hepatitis, myocarditis, nephritis, or pneumonitis or pulmonary infiltrates. DHS also is known as "drug rash with eosinophilia and systemic symptoms", the "sulfone syndrome," "glandular fever," or "anticonvulsant- or carbamazepine hypersensitivity syndrome," depending on the causative drug and context [80]. Typically, the disease develops within the first 8 weeks into treatment with anticonvulsants, with an attack rate of 1 in 5000 to 10,000 patients who are on the drug [81]. The variable presentations of DHS include dermatologic, hematologic (anemia, thrombopenia, leukemic reactions), lymphatic, or internal organ involvement and can mimic systemic diseases or an infection [80]. A high index of suspicion is required in patients who receive allopurinol; aromatic anticonvulsants, particularly carbamazepine and phenytoin; and sulfonamides. Less common inducers of DHS include abacavir, atenolol, azathioprine, bupropion, captopril, diltiazem, gold salts, leflunomide, minocycline, nevirapine, oxicam NSAIDs, sulfasalazine, and trimethoprim [2,81,82]. Often, onset is gradual, with fever and papulopustular erythematous skin reactions as the first indicators [81]. The cutaneous involvement can progress to exfoliative dermatitis. The severity or extent of the skin-related changes do not correlate with the severity or extent of internal organ involvement, which may remain asymptomatic or be life-threatening. Eosinophilia and atypical lymphocytosis occur in up to 30% of cases [81]. DHS also can be manifested by cytopenia, hemolytic anemia, transient antibody deficiency, or hypogammaglobulinemia; DHS also can mimic acute leukemia or a viral infection. The thoracic manifestations of the DHS include lymphoid interstitial pneumonia, interstitial lung disease, eosinophilic pneumonia, and pleural effusion [83]. Other organ involvement in DHS includes hepatosplenomegaly, eosinophilic myocarditis, colitis, granulomatous angiitis, a systemic lupus erythematosus-like picture with OP, and multiple organ dysfunction.

Patients who take anticonvulsants may present with diffuse lymph node enlargement as a prominent manifestation of DHS; sometimes, this is more visible in the mediastinum. Histopathology shows hyperplasia, or Reed-Sternberg cells and necrosis that mimic Hodgkin's disease [80]. Pseudolymphoma or lymphoma can diminish after drug therapy withdrawal; however, in some patients, there is relapse to uncontrollable lymphoma.

Treatment consists of immediate withdrawal of all suspect drugs, followed by supportive care of symptoms and corticosteroid therapy. Generally, drug withdrawal is followed by improvement in a few days. In a few patients, however, the disease accelerates after withdrawal [80]. The mortality rate is as high as 10% [81]. Relapse may occur as corticosteroid doses are tapered and treatment may need to be continued for months. Patients who develop DHS must avoid reexposure to the causative medication and related aromatic compounds (phenytoin, carbamazepine, phenobarbitone). Rechallenge produces relapse with increased severity [80]. Cross-reaction can occur with oxicam NSAIDs. Because genetic factors are suspected in DHS, relatives should be instructed about the symptoms of DHS and their enhanced risk of developing similar adverse reactions should they take similar medications.

Drug-induced lupus erythematosus

DI lupus has been reported with approximately 60 chemically- and pharmacologically-unrelated drugs [8,83,84], including Am, ACEI, anticonvulsants (carbamazepine, ethosuximide, phenytoin, primidone, trimethadone, and valproate, but not benzodiazepines or phenobarbital), anti-TNF agents, β-blockers (mainly acebutolol), chlorpromazine, oral contraceptives, recombinant cytokines or antibodies, dihydralazine, IFN, mesalazine, methyldopa, minocycline, nitrofurantoin, propylthiouracil, statins, sulfasalazine, and ticlopidine [2]. It is estimated that drugs cause approximately 15% to 30% of all cases of lupus. DI lupus is clinically and biologically different from the naturally-occurring lupus erythe-

matosus. DI lupus has the reputation for being diagnosed late, after long periods of disabling symptoms. The disease is diagnosed when there is the conjunction of treatment with a lupus-inducing drug; positive antinuclear antibodies without, generally, the presence of anti-double strand DNA antibodies; and suggestive clinical manifestations.

Although the prevalence of pleuropulmonary manifestations in DI lupus ranges between 15% and 60% depending on the causative drug, pulmonary infiltrates in isolation (ie, without pleural manifestations of the disease) are an unusual feature except perhaps with nitrofurantoin. Mild pulmonary infiltrates were described in one case of lupus erythematosus that was induced by lovastatin. In another case with fluvastatin-induced lupus erythematosus, diffuse pulmonary infiltrates developed that corresponded histologically to diffuse alveolar damage with reactive type 2 pneumocytes. Despite high-dose corticosteroid therapy and immunosuppressive agents, ARDS developed and the patient died. More common manifestations of DI lupus include chest pain, cough, dyspnea, arthralgias, skin changes, fever, malaise, pleuritis, and pleural or pericardial effusion. The lupus anticoagulant and antiphospholipid antibodies are present in a few patients and may be associated with thromboembolic phenomena or the hypercoagulable state. The alveolar hemorrhage syndrome is not a feature of DI lupus in contrast with naturally-occurring lupus erythematosus. Management of DI lupus consists mainly of discontinuation of the drug; corticosteroid therapy, immunosuppressives, or plasma exchange are reserved for severe reactions.

Pleuropulmonary reactions

Parenchymal changes, such as pulmonary infiltrates or subpleural foci of rounded atelectasis, can develop in patients who have DI primary pleural fibrosis (eg, ergot-induced [85], or in DI lupus [83]). The disease is then referred to as "pleuropneumonitis." The parenchymal changes may be nonspecific.

Infiltrative lung disease that results from irradiation to the chest

Thoracic irradiation causes dose-related reversible changes in the lung that are characterized by a dry cough and the pathologic changes of bizarre type II cells, hyaline membranes, edema, and eventually, fibrosis. It was later realized that the pathologic changes that were induced by alkylating agents were similar [12]. Most commonly, radiation lung injury develops in patients who receive therapy for lung or breast carcinoma, Hodgkin's disease or non-Hodgkin's lymphomas, or total body irradiation before bone marrow or peripheral stem cell transplantation. The expression of radiation injury to the lung depends upon the direction of the radiation beam. For instance, radiation therapy for lung cancer tends to induce unilateral changes, whereas mantle-field irradiation for Hodgkin's disease tends to produce upper chest and paramediastinal changes. Nonetheless, radiation therapy may induce changes in areas of the lung that are remote from the radiation beam, as suggested by three lines of evidence. First, BAL lymphocytes are increased or gallium is taken up in the nonirradiated, and in the irradiated lung. Second, organizing or eosinophilic pneumonia following breast radiation therapy may involve nonirradiated areas of the lung. Third, radiation injury may spread outside the irradiated lung to create acute severe radiation pneumonitis and ARDS. In distinction to drugs, radiation therapy may concomitantly affect the pleura, myocardium, heart valves, pericardium, pulmonary veins, mediastinum, lymphatic channels, and phrenic nerves to create multi-faceted respiratory involvement and, sometimes, pulmonary infiltrates. The risk of radiation pneumonitis depends on individual susceptibility of the host, the dose that is delivered to the lung, the daily or fractionation schedule, and a recent history of treatment with chemotherapeutic agents or oxygen. Other factors include older age and a low baseline lung function or Pa_{O_2}. Recent pneumonectomy is a potential risk factor because pulmonary reserve is compromised. Also, more remaining lung can be exposed to radiation as postpneumonectomy hemithorax contracts. Ongoing smoking may have a protective effect.

With time, several patterns of radiation pneumonitis have been recognized. Classic radiation pneumonitis, also called sporadic radiation pneumonia [12], is a common form of radiation-induced damage. Approximately 10% of patients who receive radiation therapy to the chest develop radiographic changes that are consistent with radiation pneumonitis. Symptoms include a dry cough, moderate fever, and dyspnea. On imaging, changes typically develop 1 to 2 months after the beginning of treatment, in the form of a discrete haze, ill-defined patchy nodules or an area of condensation. Typically, these changes predominate in the irradiated area and may reverse within 6 months or progress toward a well-demarcated area of fibrosis. Mild restrictive lung function can develop early in the course of radiation pneumo-

nitis; lung volumes normalize in 18 to 24 months. Rarely, a lung biopsy is needed to establish the diagnosis. Histologic features include interstitial edema, hemorrhage, and a fibrinous exudate in the early stage of the disease. Later, the appearances include distortion, fibrosis, and type 2 pneumocyte dysplasia. Patients who have radiation pneumonitis respond well to the administration of corticosteroids; however, these drugs are not required in all cases and treatment is guided by severity of symptoms and the presence of hypoxemia. Late complications of chronic radiation pneumonitis include bronchiectasis in the fibrotic area, pneumothorax, and colonization by *Aspergillus* spp. Late radiation-induced myocardial or valvular injury can be associated with chronic radiation pneumonitis and may produce pulmonary infiltrates that are related to pulmonary congestion. With the current use of three-dimensional radiation portals, resulting infiltrates from radiation may not result in the traditional straight-edged infiltrate and may be more difficult to distinguish from other entities.

Rapid extension of the infiltrates shortly after radiation therapy to the chest or in candidates for bone marrow graft who received conditioning chemotherapy and total body irradiation suggests the diagnosis of acute radiation pneumonia. In addition to radiation dose and port size, recent administration of chemotherapeutic drugs or oxygen or corticosteroid withdrawal are risk factors. Acute radiation pneumonitis is associated with significant symptoms and, in some patients, respiratory failure or ARDS. Patients may, however, respond satisfactorily to the administration of corticosteroids.

OP following radiation therapy to the breast is a recently-recognized entity. Typically, the disease is diagnosed when migratory opacities develop a few weeks to a few months after radiation therapy, in the context of mild respiratory and constitutional symptoms. Radiation-induced OP is attributed to priming of lung tissue by radiation and is controlled by corticosteroids in a manner that is not dissimilar from OP of other causes [86–88].

Recently, chronic eosinophilic pneumonia also was reported in female patients 1 to 10 (average 3.5) months after radiation therapy for breast cancer [47]. All of the patients had a history of asthma or atopy, a feature similar to other forms of iatrogenic eosinophilic pneumonia. An eosinophilia was present in blood or BAL in all cases. The radiographic appearances included pulmonary infiltrates in the irradiated lung in three women and bilateral infiltrates in the remaining two patients. In one patient, the pulmonary opacities migrated from one area of the lung to another. Corticosteroid therapy was associated with prompt recovery, although symptoms recurred after corticosteroid withdrawal as in other forms of OP.

Acknowledgments

The editorial assistance of Sarah Barth (Elsevier) and Sarah Mell (Capital City Press) is gratefully acknowledged.

References

[1] Wolff AJ, O'Donnell AE. Pulmonary effects of illicit drug use. Clin Chest Med 2004;25:203–16.
[2] Pneumotox® website. Available at: http://www.pneumotox.com [Last update: April, 2004].
[3] Camus P, Foucher P, Bonniaud P, Ask K. Drug-induced infiltrative lung disease. Eur Respir J 2001;32: 93s–100s.
[4] Flieder DB, Travis WD. Pathologic characteristics of drug-induced lung disease. Clin Chest Med 2004;25: 37–46.
[5] Camus P, Martin II WJ, Rosenow III EC. Amiodarone pulmonary toxicity. Clin Chest Med 2004;25:65–76.
[6] White DA. Drug-induced pulmonary infection. Clin Chest Med 2004;25:179–88.
[7] Kremer JM, Alarcon GS, Weinblatt ME, Kaymakcian MV, Macaluso M, Cannon GW, et al. Clinical, laboratory, radiographic, and histopathologic features of methotrexate-associated lung injury in patients with rheumatoid arthritis. Arthritis Rheum 1997;40: 1829–37.
[8] Camus P. Drug-induced infiltrative lung diseases. In: Schwarz MI, King Jr TE, editors. Infiltrative lung diseases. 4th edition. Hamilton (Ontario): B C Dekker, Inc.; 2003. p. 485–534.
[9] Camus P. Drug history and remote exposure to drugs. A cause of lung disease? Eur Respir J 2000;16:381–4.
[10] Pirmohamed M, Naisbitt DJ, Gordon F, Park BK. The danger hypothesis - potential role in idiosyncratic drug reactions. Toxicology 2002;181–2:55–63.
[11] Cleverley JR, Screaton NJ, Hiorns MP, Flint JD, Müller NL. Drug-induced lung disease: high-resolution CT and histological findings. Clin Radiol 2002;57:292–9.
[12] Abratt RP, Onc FR, Morgan GW, Silvestri G, Willcox P. Pulmonary complications of radiation therapy. Clin Chest Med 2004;25:167–77.
[13] Lee-Chiong TLJ, Matthay RA. Drug-induced pulmonary edema and acute respiratory distress syndrome. Clin Chest Med 2004;25:95–104.
[14] Kopko PM, Holland PV. Transfusion-related lung injury. Br J Haematol 1999;105:322–9.
[15] Logan PM, Primack SL, Staples C, Miller RR, Müller NL. Acute lung disease in the immunocompromised host. Diagnostic accuracy of the chest radiograph. Chest 1995;108:1283–7.

[16] Zisman DA, McCune WJ, Tino G, Lynch JPI. Drug-induced pneumonitis: the role of methotrexate. Sarcoidosis Vasc Diffuse Lung Dis 2001;18:243–52.
[17] Lock BJ, Eggert M, Cooper Jr JAD. Infiltrative lung disease due to noncytotoxic agents. Clin Chest Med 2004;25:47–52.
[18] Cannon GW. Methotrexate pulmonary toxicity. Rheum Dis Clin North Am 1997;23:917–37.
[19] Verra F, Hmouda H, Rauss A, Lebargy F, Cordonnier C, Bignon J, et al. Bronchoalveolar lavage in immunocompromised patients. Clinical and functional consequences. Chest 1992;101:1215–20.
[20] Fuhrman C, Parrot A, Wislez M, Prigent H, Boussaud V, Bernaudin JF, et al. Spectrum of CD4 to CD8 T-cell ratios in lymphocytic alveolitis associated with methotrexate-induced pneumonitis. Am J Respir Crit Care Med 2001;164:1186–91.
[21] Kane GC, Troshinsky MB, Peters SP, Israel HL. *Pneumocystis carinii* pneumonia associated with weekly methotrexate: cumulative dose of methotrexate and low CD_4 cell count may predict this complication. Respir Med 1993;87:153–5.
[22] Clearkin R, Corris PA, Thomas SHL. Methotrexate pneumonitis in a patient with rheumatoid arthritis. Postgr Med J 1997;73:603–4.
[23] Imokawa S, Colby TV, Leslie KO, Helmers RA. Methotrexate pneumonitis: review of the literature and histopathological findings in nine patients. Eur Respir J 2000;15:373–81.
[24] Limper AH. Chemotherapy-induced lung disease. Clin Chest Med 2004;25:53–64.
[25] Costabel U, Uzaslan E, Guzman J. Bronchoalveolar lavage in drug-induced lung disease. Clin Chest Med 2004;25:25–36.
[26] Donaldson L, Grant IS, Naysmith MR, Thomas JS. Acute amiodarone-induced lung toxicity. Intensive Care Med 1998;24:626–30.
[27] Liverani E, Armuzzi A, Mormile F, Anti M, Gasbarrini G, Gentiloni N. Amiodarone-induced adult respiratory distress syndrome after nonthoracotomy subcutaneous defibrillator implantation. J Intern Med 2001;249:565–6.
[28] van Mieghem W, Coolen L, Malysse I, Lacquet LM, Deneffe GJD, Demedts MGP. Amiodarone and the development of ARDS after lung surgery. Chest 1994;105:1642–5.
[29] Rady MY, Ryan T, Starr NJ. Preoperative therapy with amiodarone and the incidence of acute organ dysfunction after cardiac surgery. Anesth Analg 1997;85:489–97.
[30] Gehlbach BK, Geppert E. The pulmonary manifestations of left heart failure. Chest 2004;125:669–82.
[31] Bristedt P, Tylén U. Pulmonary edema following intravenous injection of nonionic low-osmolar contrast medium - Appearance on HRCT - A case report. Acta Radiol 1998;39:81–3.
[32] Kopko PM, Popovsky MA. Pulmonary injury from transfusion-related acute lung injury. Clin Chest Med 2004;25:105–13.
[33] Schwarz MI, Fontenot AP. Drug-induced diffuse alveolar hemorrhage syndromes and vasculitis. Clin Chest Med 2004;25:133–40.
[34] Freemer MM, King Jr TE. Connective tissue diseases. In: Schwarz MI, King Jr TE, editors. Infiltrative lung diseases. 4th edition. Hamilton (Ontario): B C Dekker, Inc.; 2003. p. 535–98.
[35] Choi HK, Merkel PA, Walker AM, Niles JL. Drug-associated antineutrophil cytoplasmic antibody-positive vasculitis: prevalence among patients with high titers of antimyeloperoxidase antibodies. Arthritis Rheum 2000;43:405–13.
[36] Fontenot AP, Schwarz MI. Diffuse alveolar hemorrhage. In: Schwarz MI, King Jr TE, editors. Infiltrative lung diseases. 4th edition. Hamilton (Ontario): B C Dekker, Inc.; 2003. p. 632–56.
[37] Choi HK, Merkel PA, Cohen-Tervaert JW, Black RM, McCluskey RT, Niles JL. Alternating antineutrophil cytoplasmic antibody specificity. Drug-induced vasculitis in a patient with Wegener's granulomatosis. Arthritis Rheum 1999;42:384–8.
[38] Cohen AJ, King Jr TE, Downey GP. Rapidly progressive bronchiolitis obliterans with organizing pneumonia. Am J Respir Crit Care Med 1994;149:1670–5.
[39] Epler GR. Drug-induced bronchiolitis obliterans organizing pneumonia. Clin Chest Med 2004;25:89–94.
[40] Beasley MB, Franks TJ, Galvin JR, Gochuico B, Travis WD. Acute fibrinous and organizing pneumonia. A histologic pattern of lung injury and possible variant of diffuse alveolar damage. Arch Pathol Lab Med 2002;126:1064–70.
[41] Nizami IY, Kissner DG, Vissher DW, Dubaybo BA. Idiopathic bronchiolitis obliterans with organizing pneumonia. An acute and life-threatening syndrome. Chest 1995;108:271–7.
[42] Pfitzenmeyer P, Foucher P, Piard F, Coudert B, Braud ML, Gabez P, et al. Nilutamide pneumonitis: a report on eight patients. Thorax 1992;47:622–7.
[43] Akira M, Ishikawa H, Yamamoto S. Drug-induced pneumonitis: thin-section CT findings in 60 patients. Radiology 2002;224:852–60.
[44] Bone RC, Wolfe J, Sobonya RE, Kerby GR, Stechschulte D, Ruth WE, et al. Desquamative interstitial pneumonia following long-term nitrofurantoin therapy. Am J Med 1976;60:697–701.
[45] Allen JN. Drug-induced eosinophilic lung disease. Clin Chest Med 2004;25:77–88.
[46] Pfitzenmeyer P, Meier M, Zuck P, Peiffer G, Masson P, Turcu A, et al. Piroxicam-induced pulmonary infiltrates and eosinophilia. J Rheumatol 1994;21:1573–7.
[47] Cottin V, Frognier R, Monnot H, Levy A, De Vuyst P, Cordier JF. Chronic eosinophilic pneumonia after radiation therapy for breast cancer. Eur Respir J 2004;23:9–13.
[48] Sitbon O, Bidel N, Dussopt C, Azarian R, Braud ML, Lebargy F, et al. Minocycline pneumonitis and eosinophilia: a report on 8 patients. Arch Intern Med 1994;154:1633–40.
[49] Camus P. Drug-induced pleural disease. In: Bouros D,

Lenfant C, editors. Pleural disorders. New York: M Dekker; 2004. p. 317–52.
[50] Camus P, Piard F, Ashcroft T, Gal AA, Colby TV. The lung in inflammatory bowel disease. Medicine (Baltimore) 1993;72:151–83.
[51] Sunderji R, Kanji Z, Gin K. Pulmonary effects of low dose amiodarone: a review of the risks and recommendations for surveillance. Can J Cardiol 2000;16: 1435–40.
[52] Stelfox HT, Ahmed SB, Fiskio J, Bates DW. Monitoring amiodarone's toxicities: recommendations, evidence, and clinical practice. Clin Pharmacol Ther 2004;75:110–22.
[53] Malhorta A, Muse VV, Mark EJ. An 82-year-old man with dyspnea and pulmonary abnormalities. Case Records of the Massachusetts General Hospital - Case 12-2003. N Engl J Med 2003;348:1574–85.
[54] Vernhet H, Bousquet C, Durand G, Giron J, Senac JP. Reversible amiodarone-induced lung disease: HRCT findings. Eur Radiol 2001;11:1697–703.
[55] Erasmus JJ, McAdams HP, Rossi SE. High-resolution CT of drug-induced lung disease. Radiol Clin North Am 2002;40:61–72.
[56] Ott MC, Khoor A, Leventhal JP, Paterick TE, Burger CD. Pulmonary toxicity in patients receiving low-dose amiodarone. Chest 2003;123:646–51.
[57] Rossi SE, Erasmus JJ, McAdams P, Sporn TA, Goodman PC. Pulmonary drug toxicity: radiologic and pathologic manifestations. Radiographics 2000;5: 1245–59.
[58] Siniakowicz RM, Narula D, Suster B, Steinberg JS. Diagnosis of amiodarone pulmonary toxicity with high-resolution computerized tomographic scan. J Cardiovasc Electrophysiol 2001;12:431–6.
[59] Chouri N, Langin T, Lantuejoul S, Coulomb M, Brambilla C. Pulmonary nodules with the CT halo sign. Respiration (Herrlisheim) 2002;69:103–6.
[60] Coudert B, Bailly F, André F, Lombard JN, Camus P. Amiodarone pneumonitis: bronchoalveolar lavage findings in 15 patients and review of the literature. Chest 1992;102:1005–12.
[61] Bedrossian CW, Warren CJ, Ohar J, Bhan R. Amiodarone pulmonary toxicity: cytopathology, ultrastructure, and immunocytochemistry. Ann Diagn Pathol 1997;1: 47–56.
[62] Ryu JH, Myers J, Swenson SJ. Bronchiolar disorders. Am J Respir Crit Care Med 2003;168:1277–92.
[63] Weyl Ben Arush M, Roguin A, Zamir E, Et-Hassid R, Pries D, Gaitini D, et al. Bleomycin and cyclophosphamide toxicity simulating metastatic nodules to the lungs in childhood cancer. Pediatr Hematol Oncol 1997;14: 381–6.
[64] Camus P, Lombard JN, Perrichon M, Guerin JC, Bejui-Thivolet F, Piard F, et al. Bronchiolitis obliterans organising pneumonia in patients taking acebutolol or amiodarone. Thorax 1989;44:711–5.
[65] Cameron RJ, Kolbe J, Wilsher ML, Lambie N. Bronchiolitis obliterans organising pneumonia associated with the use of nitrofurantoin. Thorax 2000;55: 249–51.
[66] O'Driscoll BR, Hasleton PS, Taylor PM, Poulter LW, Gattamaneni HR, Woodcock AA. Active lung fibrosis up to 17 years after chemotherapy with carmustine (BCNU) in childhood. N Engl J Med 1990;323: 378–82.
[67] O'Driscoll BR, Kalra S, Gattamaneni HR, Woodcock AA. Late carmustine lung fibrosis. Age at treatment may influence severity and survival. Chest 1995;107: 1355–7.
[68] Malik SW, Myers JL, DeRemee RA, Specks U. Lung toxicity associated with cyclophosphamide use. Two distinct patterns. Am J Respir Crit Care Med 1996; 154:1851–6.
[69] Tucker AS, Newman AJ, Alvorado C. Pulmonary, pleural and thoracic changes complicating chemotherapy. Radiology 1977;125:805–99.
[70] Lin M. Radiation pneumonitis caused by Yttrium-90 microspheres: radiologic findings. Am J Roentgenol 1994;162:1300–22.
[71] Fourme T, Vieillard-Baron A, Loubières Y, Julie C, Page B, Jardin F. Early fat embolism after liposuction. Anesthesiology 1998;89:782–4.
[72] Lekka ME, Liokatis S, Nathanail C, Galani V, Nakos G. The impact of intravenous fat emulsion administration in acute lung injury. Am J Respir Crit Care Med 2004; 169:638–44.
[73] Gulbahce HE, Pambuccian SE, Jessurun J, Woodard P, Steiner ME, Manivel JC, et al. Pulmonary nodular lesions in bone marrow transplant recipients. Impact of histologic diagnosis on patient management and prognosis. Am J Clin Pathol 2004;121:205–10.
[74] Gondouin A, Manzoni P, Ranfaing E, Brun J, Cadranel J, Sadoun D, et al. Exogenous lipid pneumonia: a retrospective multicentre study of 44 cases in France. Eur Respir J 1996;9:1463–9.
[75] Prakash UB, Rosenow III EC. Pulmonary complications from ophthalmic preparations. Mayo Clin Proc 1990;65:521–9.
[76] Drent M, Cobben NAM, Henderson RF, Jacobs JA, Wouters EFM, van Dieijen-Visser MP. BAL fluid LDH activity and LDH isoenzyme pattern in lipoid pneumonia caused by an intravenous injection of lamp oil. Eur Respir J 1996;9:2416–8.
[77] Franquet T, Gimenez A, Bordes R, Rodriguez-Arias JM, Castella J. The crazy-paving pattern in exogenous lipoid pneumonia: CT-pathologic correlation. Am J Roentgenol 1998;170:315–7.
[78] Kennedy JD, Costello P, Balikian JP, Herman PG. Exogenous lipoid pneumonia. Am J Roentgenol 1981; 136:1145–9.
[79] Tahan V, Ozseker F, Guneylioglu D, Baran A, Ozaras R, Mert A, et al. Sarcoidosis after use of interferon for chronic hepatitis C—report of a case and review of the literature. Dig Dis Sci 2003;48:169–73.
[80] de Vriese ASP, Philippe J, Van Renterghem DM, De Cuyper CA, Hindryckx PHF, Matthys EGJ, et al. Car-

bamazepine hypersensitivity syndrome: report of 4 cases and review of the literature. Medicine (Baltimore) 1995;74:144–50.

[81] Rademaker M, Maling T. Drug-hypersensitivity syndrome. Available at: http://www.medsafe.govt.nz. Accessed April 2004.

[82] Pichler WJ. Delayed drug hypersensitivity reactions. Ann Intern Med 2003;139:683–93.

[83] Camus P. Drug-induced respiratory disease in connective tissue diseases. In: Wells AU, Denton CP, editors. Handbook of systemic autoimmune diseases part VI: pulmonary involvement in systemic autoimmune diseases. In press.

[84] Adkinson NFJ, Essayan D, Gruchalla R, Haggerty H, Kawabata T, Sandler JD, et al. Task force report: future research needs for the prevention and management of immune-mediated drug hypersensitivity reactions. J Allergy Clin Immunol 2002;109:S461–78.

[85] Pfitzenmeyer P, Foucher P, Dennewald G, Chevalon B, Debieuvre D, Bensa P, et al. Pleuropulmonary changes induced by ergoline drugs. Eur Respir J 1996; 9:1013–9.

[86] Bayle JY, Nesme P, Bejui-Thivolet F, Loire R, Guérin JC, Cordier JF. Migratory organizing pneumonitis "primed" by radiation therapy. Eur Respir J 1995;8: 322–6.

[87] Crestani B, Kambouchner M, Soler P, Crequit J, Brauner M, Battesti JP, et al. Migratory bronchiolitis obliterans organizing pneumonia after unilateral radiation therapy for breast carcinoma. Eur Respir J 1995;8: 318–21.

[88] Stover DE, Milite F, Zakowski M. A newly recognized syndrome—radiation related bronchiolitis obliterans and organizing pneumonia. Respiration (Herrlisheim) 2001;68:540–4.